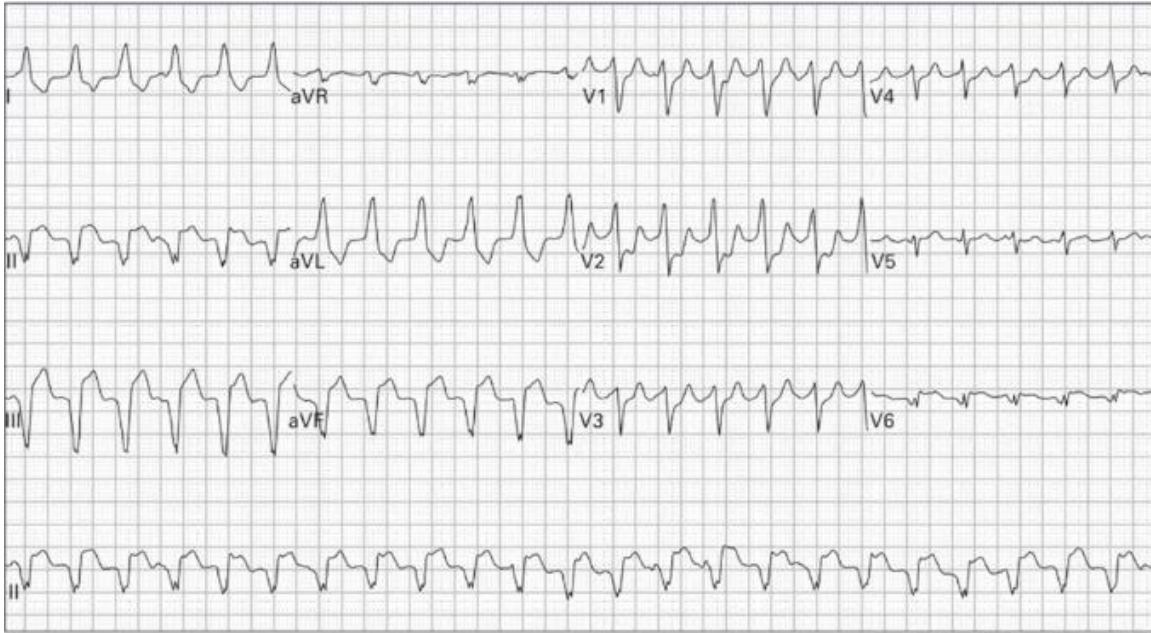
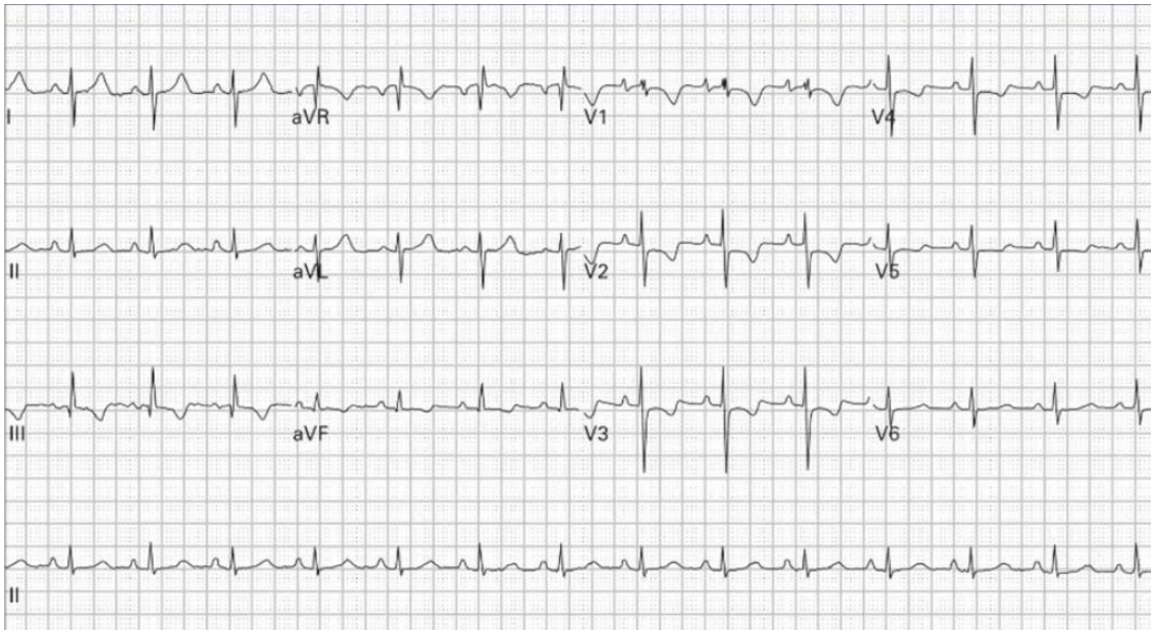


ECG interpretation of life threatening arrhythmias  
Questions

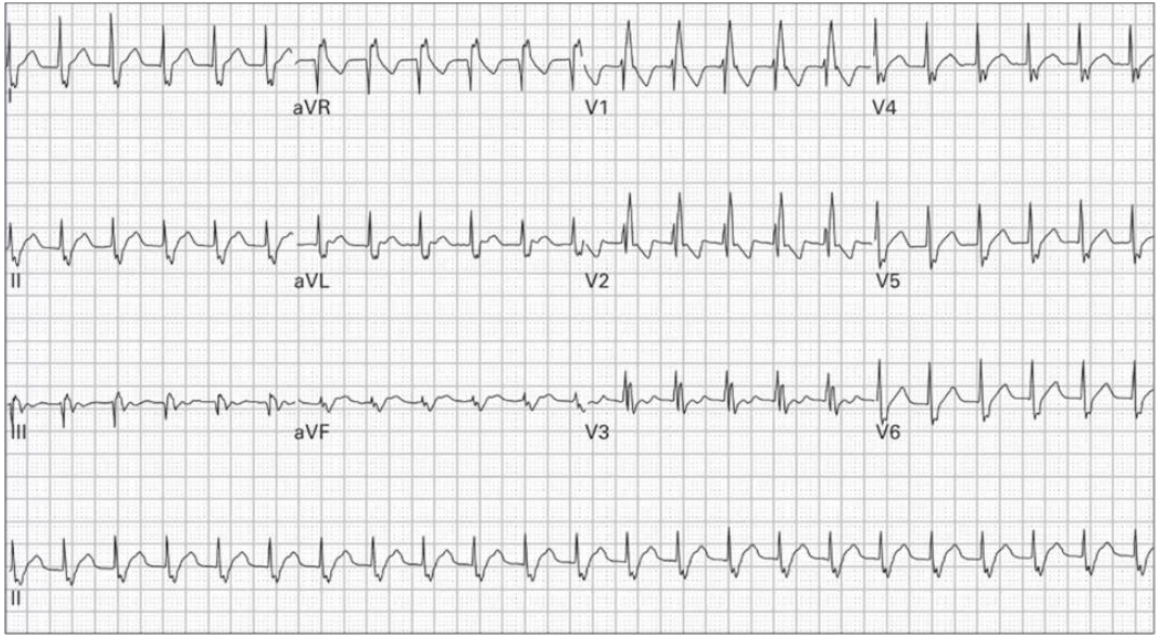
1)



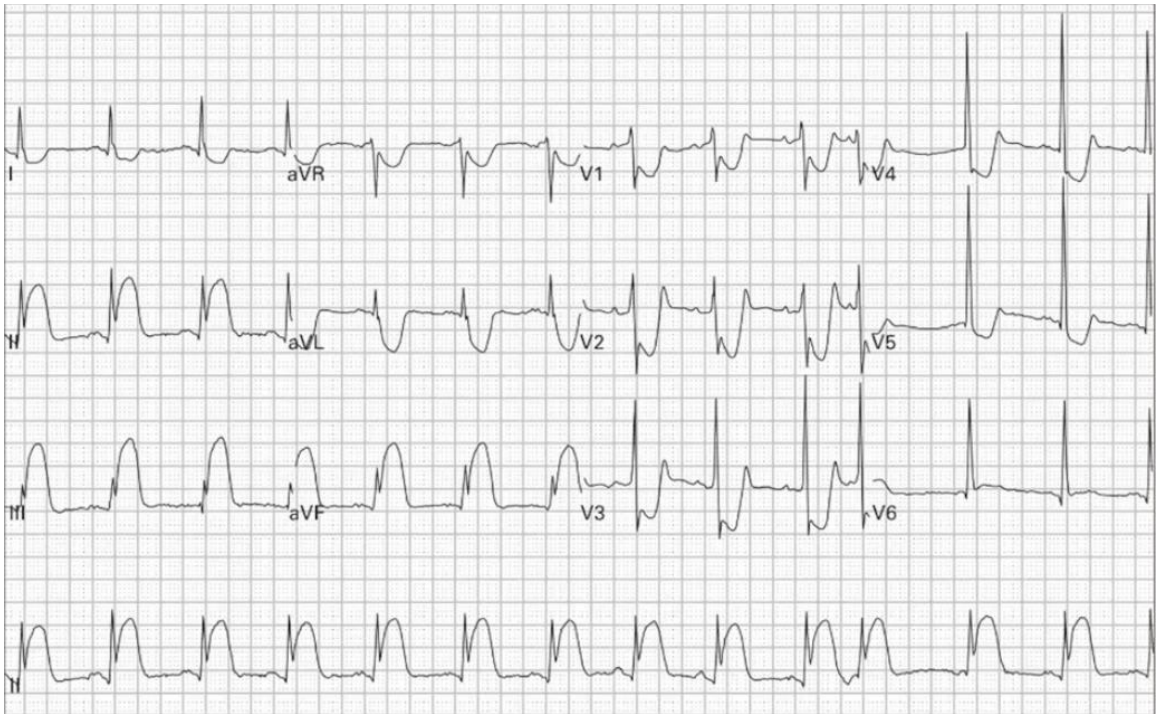
2)



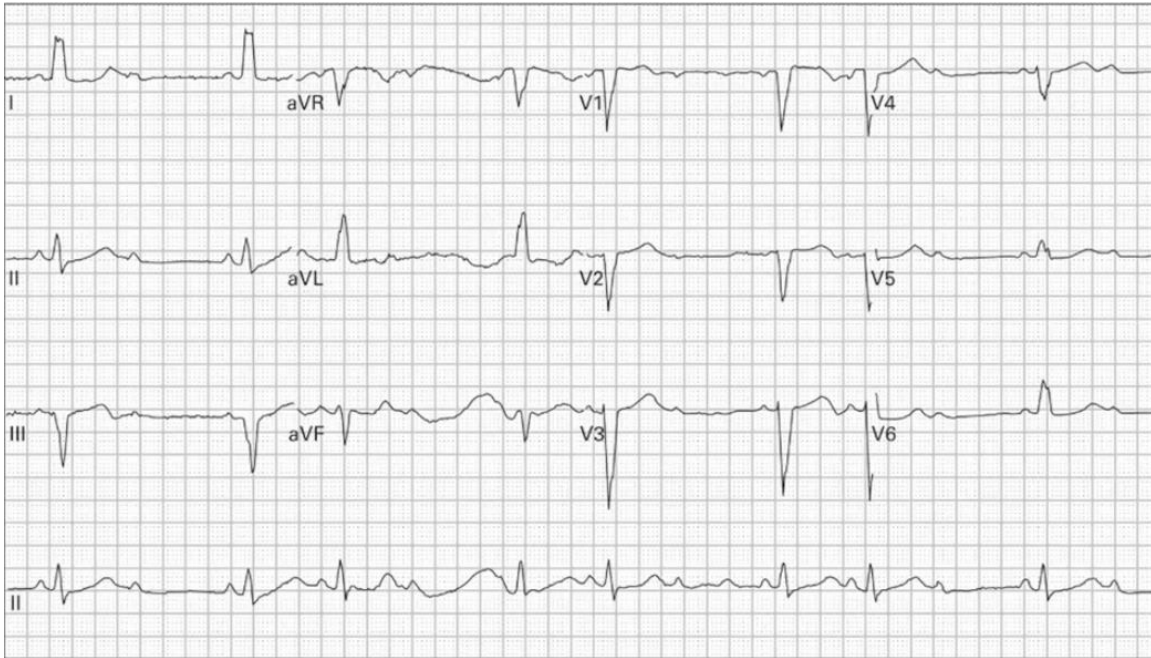3)



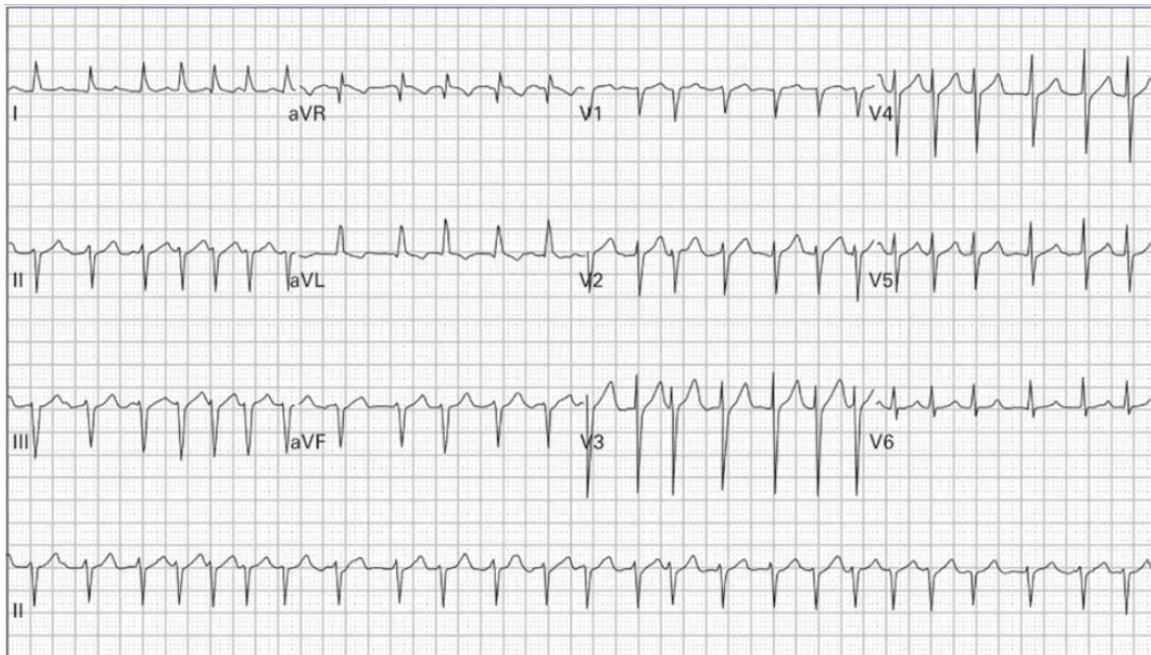
4)



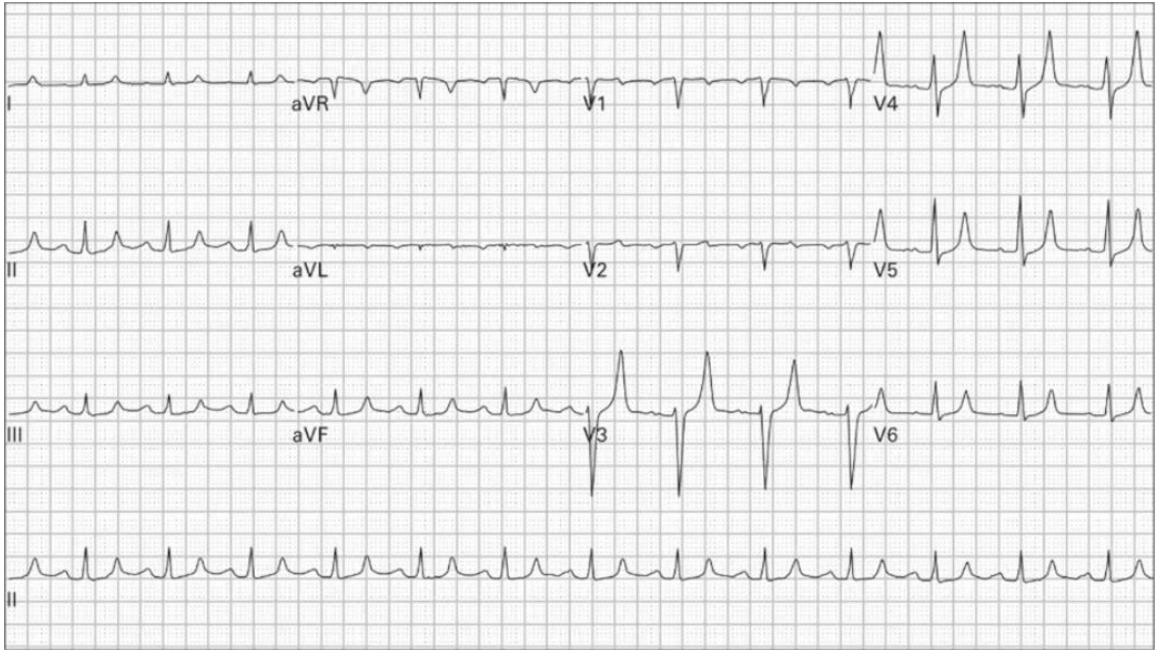5)



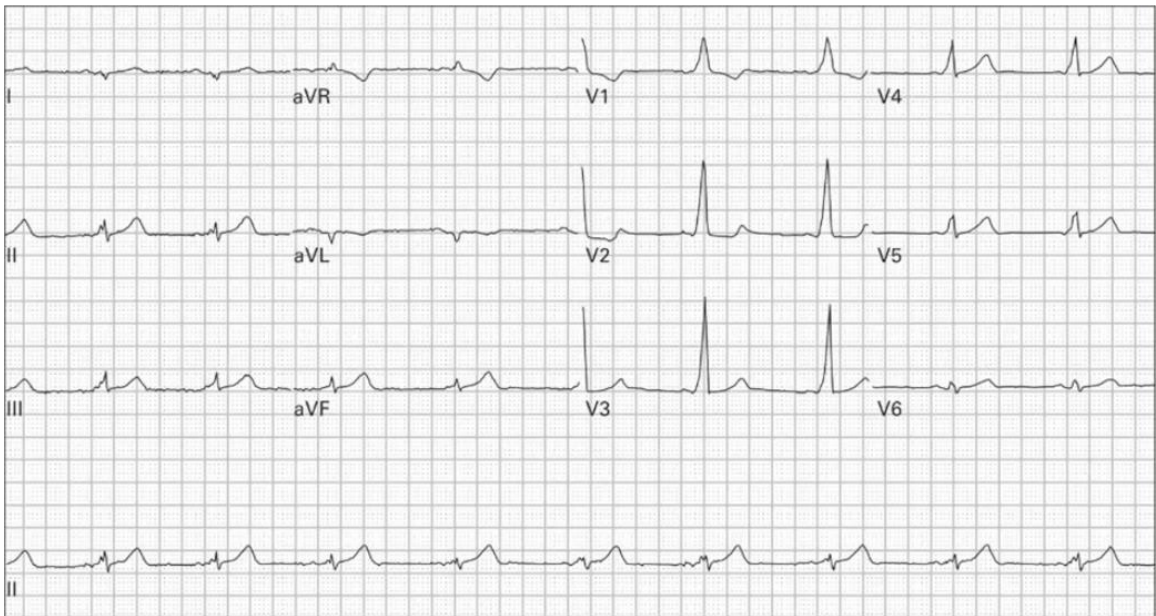
6)



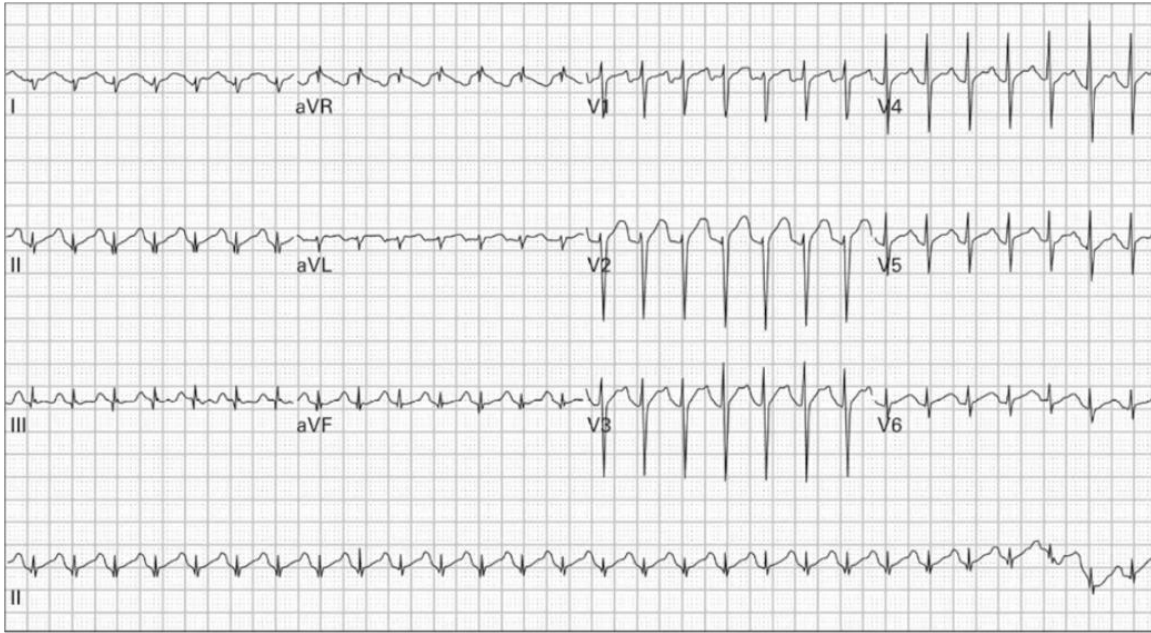
7)



8)



9)



10)

