

# Western Trauma Association (WTA) Critical Decisions in Trauma: Management of Adult Blunt Splenic Trauma

Frederick A. Moore, MD, James W. Davis, MD, Ernest E. Moore, Jr., MD, Christine S. Cocanour, MD, Michael A. West, MD, and Robert C. McIntyre, Jr., MD

*J Trauma.* 2008;65:1007–1011.

This is a position article from members of the Western Trauma Association (WTA). Because there are no prospective randomized trials, the algorithm (Fig. 1) is based on the expert opinion of WTA members and published observational studies. We recognize that variability in decision making will continue. We hope this management algorithm will encourage institutions to develop local protocols based on the resources that are available and local expert consensus opinion to apply the safest, most reliable management strategies for their patients. What works at one institution may not work at another. The algorithm contains letters A through K, which corresponds to lettered text. This text is intentionally concise and its purpose is to navigate the reader through the algorithm and to identify and discuss the gray zones in the logic of this decision making. This annotated algorithm is intended to (a) serve as a quick reference for bedside clinicians, (b) foster more detailed patient care protocols that will allow for prospective collection of data to identify best practices, and (c) generate research projects to answer specific questions concerning decision making in the management of adult blunt splenic trauma.

## Historic Perspective

Management of blunt splenic trauma has changed drastically during the past 30 years. In the mid-1970s, recognition of the spleen's immunologic importance and the lifelong risk of overwhelming postsplenectomy sepsis provided the rationale for avoiding splenectomy. Although the adult sur-

geons were focused on perfecting operative splenic salvage techniques,<sup>1–3</sup> the pediatric surgeons provided convincing evidence that the best way to salvage the spleen was not to operate.<sup>4–6</sup> Adult trauma surgeons were slow to adopt non-operative management (NOM) because early reports of its use in adults documented a 30% to 70% failure rate of which two-thirds underwent total splenectomy.<sup>7–10</sup> There was also a concern about missing serious concomitant intra-abdominal injuries.<sup>11–13</sup> However, with increasing experience with NOM, recognition that negative laparotomies caused significant morbidity and the availability of higher quality computerized tomographic (CT) scanning, NOM became the standard of care for adults by the mid-1990s.<sup>14–19</sup> Over the next decade, the percentage of patients in which NOM was pursued increased from 30% to 60% to as high as 85% as previous expert opinion contra-indications (e.g. advanced age, fear of missing a hollow viscus injury (HVI), >2 units of packed red blood cell transfusion, neurologic impairment, and high grades injuries) were refuted.<sup>20–26</sup> Additionally, angio-embolization (AE) was increasingly used as a NOM adjunct, and the reported failure rate of 12% to 13% dropped to as low as 2%.<sup>27–36</sup> It is unclear whether this decrease in the failure rate is due to the success of AE or more liberal definitions of failure. Table 1 lists the most recent updated series of adult splenic trauma from US trauma centers (series with >150 cases published since 2000). Variability in management strategies still exist. Important factors that drive management decisions in these trauma centers include (a) presence and severity of hemodynamic instability, (b) results of the initial workup of blunt abdominal trauma, which includes some combination of the focused abdominal sonography for trauma (FAST) examination, abdominal CT scan, and diagnostic peritoneal aspirate or diagnostic peritoneal lavage, (c) availability and indications for angiography, (d) definition of failure, and (e) use of follow-up abdominal CT scanning.

Submitted for publication April 17, 2008.

Accepted for publication August 14, 2008.

Copyright © 2008 by Lippincott Williams & Wilkins

From the Weill Cornell Medical College (F.A.M.), New York, New York; University of California, San Francisco (J.W.D.), San Francisco, California; University of Colorado Health Science Center (E.E.M., R.C.M.), Denver, Colorado; University of California Davis Medical Center (C.S.C.), Sacramento, California; and Northwestern University (M.A.W.), Chicago, Illinois.

Presented at the 38th Annual Meeting of the Western Trauma Association February 24–March 1, 2008, Squaw Creek, Olympic Valley, California.

Address for reprints: Frederick A. Moore, MD, Department of Surgery, 6550 Fannin Street, SM1661A, Houston, TX 77030; email: famoore@tmhs.org.

DOI: 10.1097/TA.0b013e31818a93bf

## Annotated Text For Figure 1

A. The initial assessment of patients with suspected blunt abdominal trauma should focus on the abdominal examination (tenderness and abdominal wall ecchymosis), vital signs, and response to resuscitation. In patients with evidence of shock or overt serious injury, blood should be

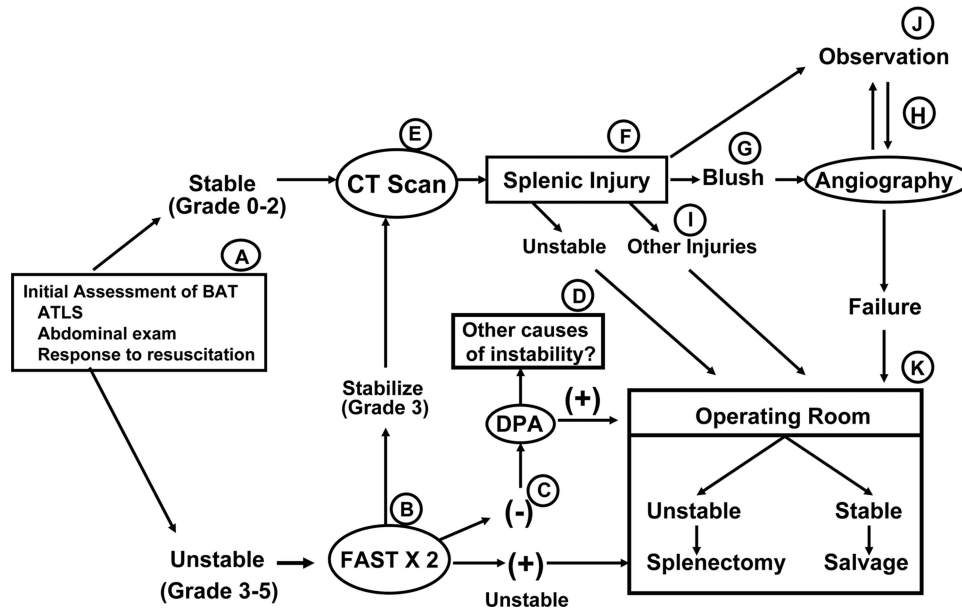


Fig. 1. Adult blunt splenic trauma.

**Table 1** Updated United States Adult Splenic Trauma Case Series Since 2000

	Total	NOM, n (%)	Angio (%)	Failure (%)	Mortality (%)
UT Houston 2000 <sup>21</sup>	461	276 (58%)	NR	13%	1%
UT Knoxville 2001 <sup>35</sup>	542	407 (75%)	0%	8%	5%
UT San Antonio 2004 <sup>29</sup>	168	139 (83%)	10%	2%	NR
University of Michigan 2004 <sup>30</sup>	164	131 (80%)	18%	5%	NR
University of Maryland 2005 <sup>31</sup>	648	368 (57%)	81%	8%	NR
Case Western 2005 <sup>32</sup>	403	344 (85%)	25%	2%	1%
UT Memphis 2007 <sup>33</sup>	426	341 (80%)	12%	4%	4%*
University of Pittsburgh 2007 <sup>34</sup>	570	349 (61%)	13%	9%	4%

\* One death attributed to nonoperative management (NOM).  
NR, not reported.

immediately drawn for laboratory testing including complete blood count, electrolytes, markers of metabolic stress (base deficit or lactate), coagulation profile, and blood typing. Adequate intravenous (IV) access should be obtained for resuscitation and potential IV contrast administration. There is considerable variability in the definition of hemodynamic instability and there is no validated scoring system. Table 2 depicts a modified hemodynamic instability score.<sup>36</sup> Systolic blood pressure <90 mm Hg to define significant hypotension and heart rate >130 beat per minute to define serious tachycardia was taken from the recently published guidelines for shock resuscitation developed by the National Institutes of Health sponsored Glue Grant consortium.<sup>37</sup> Baseline systolic blood pressure and heart rate, how they response to initial advanced trauma life support recommended volume loading and the need for ongoing for resuscitation are used to grade hemodynamic instability. We propose that this score be used for early triage decision making and be validated in prospective studies. Stable patients (grade 0–2) should be triaged to the CT scanner.

**Table 2** Hemodynamic Instability Score<sup>38</sup>

- Grade 0: No significant hypotension (systolic blood pressure [SBP] <90 mm Hg) or serious tachycardia (heart rate [HR] >130)
- Grade 1: Hypotension or tachycardia by report but none recorded in emergency department (ED)
- Grade 2: Hypotension or tachycardia responsive to initial volume loading with no ongoing fluid or PRBC requirement
- Grade 3: Hypotension or tachycardia responsive to initial volume loading with modest ongoing fluid (<250 mL/h) or PRBC requirement
- Grade 4: Hypotension or tachycardia only responsive to >2 L of volume loading and the need for vigorous ongoing fluid infusion (>250 mL/h) and PRBC transfusion
- Grade 5: Hypotension unresponsive to fluid and PRBC transfusion

B. Unstable patients (grade 3–5) should have a FAST examination done (if available and reliable) after the initial ABCs. Patients who stabilize with initial volume loading and require modest ongoing resuscitation (grade 3) may be triaged to the CT scanner if readily available. Grade 3 patients who are FAST (+) are presumed to have a hemoperitoneum. This information should prompt closer

monitoring and quicker processing through the CT scanner. On the other hand, FAST (+) patients who require vigorous ongoing resuscitation (grade 4 and 5 instability) should be triaged to the operating room (OR). In some cases patients with grade 4 instability might be triaged to the CT scanner with caution. This would be a reasonable option if the CT scanner is readily available and (a) a plausible explanation for instability exists (e.g., tension pneumothorax, pelvic fracture, neurogenic shock), or (b) the CT scan results will change triage decision making (e.g., epidural hematoma requiring craniotomy, torn thoracic aorta requiring thoracotomy, massive brain injury to declare futility, or vascular blush associated with a pelvic fracture prompting AE).

- C. A negative FAST does not reliably exclude intraperitoneal hemorrhage and should be repeated again as part of the secondary survey. Grade 5 instability with a negative FAST examination is an uncomfortable scenario. It is not prudent to triage this patient to the CT scanner, rather this patient should stay in the trauma resuscitation room and differential diagnosis of refractory shock should be pursued. If a missed source of hemorrhage is still a concern, despite a second negative FAST in an unstable patient, a diagnostic peritoneal aspirate should be considered. A viable alternative is to go directly to the OR in patients at risk of imminent cardiac arrest for exploratory laparotomy.
- D. Other causes of persistent instability include exsanguinating hemorrhage from a severe pelvic fracture and massive hemothorax, whereas causes of nonhemorrhagic shock include tension pneumothorax, cardiac tamponade, myocardial contusion or infarction, air embolism, and neurogenic shock.
- E. Abdominal CT scanning is the gold standard diagnostic test if NOM is to be pursued. Appropriate timing of IV contrast is crucial to define the extent of splenic injury and identify vascular blushes. Controversy exists over the need for oral contrast to diagnose HVI and its potential for causing severe aspiration pneumonitis.<sup>38</sup>
- F. Although the grade of splenic injury (Table 3) does correlate with success of NOM, it is not accurate enough to predict failure or success in individual patients.<sup>39,40</sup> There is a selection bias in who gets a CT scan. Patients with high grade injuries who are bleeding profusely are triaged early to the OR based on grade of instability and the results of the FAST examination. Additionally, in blunt trauma the spleen tends to fracture along the relatively avascular plains between the segmental polar arteries. As a result, the severity of the injury seems severe because there is a deep laceration into the parenchyma but there is only limited bleeding.
- G. As CT scanning technology has improved, more blushes are being seen and these may be helpful in predicting failure of NOM. A modified Splenic Injury Scale that incorporates vascular blush information into the anatomic descriptions used in the American Association for the

**Table 3 American Association for the Surgery of Trauma Splenic Injury Scale (1994 Revision)<sup>42</sup>**

Grade*	Injury Description
I	Hematoma subcapsular, <10% surface area Laceration capsular, <1 cm parenchymal depth
II	Hematoma subcapsular, 10–50% surface area, <5 cm diameter Laceration, 1–3 cm depth which does not involve trabecular vessel
III	Hematoma subcapsular, >50% surface area or expanding Ruptured subcapsular or parenchymal hematoma Intrapaenychymal hematoma >5 cm or expanding Laceration >3 cm depth or involving trabecular vessel
IV	Laceration involving segmental or hilar vessels producing major Devascularization (>25% of spleen)
V	Laceration, completely shattered spleen Vascular, hilar vascular injury which devascularizes spleen

\* Advance one grade for multiple injuries, up to grade 3.

Surgery of Trauma scoring system has been developed but needs validation.<sup>41</sup>

At this point in time, if vascular blush is seen on the initial CT scan and the patient is hemodynamically stable, screening angiography may be used as an adjunct to NOM based on local consensus. In patients with grade 3–4 hemodynamic instability, triage to the OR is prudent unless intervention radiology is immediately available. Patients with grade 5 instability should be taken directly to the OR. If a blush is seen on a delayed follow-up CT scan, screening angiography is recommended in the hemodynamically stable patient. There is considerable variability in the use of angiography across centers (Table 1). Although more aggressive use of angiography is associated with the highest rates of NOM (>80%) and the lowest rates of failure (2–5%), there is ongoing debate over the optimal use of this intervention because it is labor intensive and there have been several reports that document a surprisingly high rate of complications.<sup>27,28</sup> In our WTA multi-institutional experience, we reported on 140 patients who underwent AE, of which 27 (20%) suffered major complications including 16 (11%) failure to control bleeding (requiring 9 splenectomies and 7 repeat AE), 4 (3%) missed injuries, 6 (4%) splenic abscesses, and 1 iatrogenic vascular injury.

H. Arteriography requires transport to the interventional radiologist suite, where the patient should be monitored to the same standards as an intensive care unit. Therapeutic embolization is done if an aneurysm, arteriovenous fistula, or extravasation is found on the screening angiogram. There is some controversy over the optimal method of AE (i.e., main splenic artery embolization vs. distal selective artery embolization vs. combination). Main splenic artery embolization reduces bleeding by reducing perfusion pressure, but this may not prevent late

pseudoaneurysm rupture and will likely not treat an arteriovenous fistula.<sup>42</sup> On the other hand, distal selective embolization can effectively stop blood flow in polar arteries but can result in tissue infarction with local abscess formation. Local expert consensus should standardize these practices and prospectively characterize patient outcomes to define the best technique.

- I. When pursuing NOM of splenic injuries it is important to exclude other injuries that require operative intervention. Historically, the risk of missing a HVI received the most attention. In the eight recent series depicted in Table 1, where the average frequency of NOM was 70%, there was only one case of a missed HVI in the 2,355 patients selected for NOM. This was a missed colon injury and accounted for the only death in these series attributable to NOM.
- J. When failure due to bleeding is dichotomized as before or after 48 hours (early vs. late), there is a low but disturbing incidence of late bleeds (2–4%) presumably due to delayed rupture of splenic artery pseudoaneurysms.<sup>26,43,44</sup> These late bleeds tend to occur at 4 days to 8 days, but some occur weeks later. The practice of obtaining follow-up CT scans is also quite variable. The University of Tennessee Memphis group has championed the concept of obtaining CT scans before early hospital discharge of patients with high grade splenic injuries. However, their most recent series demonstrates that roughly a quarter of pseudoaneurysms occurred in grade 1 and 2 injuries and over half occurred in grade 3 injuries. This is another issue that requires prospective study before definitive recommendations can be made. In general, follow-up CT scans as out patients are not helpful but may be used selectively to confirm healing in patients who are asking to be released to pursue high risk behavior (such a bull riding or football).
- K. The decision of whether to perform a splenectomy is dependent on the patient's condition and associated injuries. Unfortunately, most patients go to the OR because of hemodynamically instability and splenectomy is the most prudent option. Splenic salvage should be pursued in the hemodynamically stable patient. Techniques include topical hemostatic agents, argon beam coagulation, direct suture repair, partial resection, wrapping the spleen with absorbable mesh, and splenic reimplantation. Pledgets are generally used when suturing splenic lacerations and margins of segmental resections. It is important to confirm hemostasis before closure of the midline fascia. Packing of the spleen in damage control surgery should be discouraged because splenectomy is fairly simple and definitive. Splenic reimplantation in a patient without significant bacterial contamination is a safe but unproven method of preserving splenic function to protect against overwhelming postsplenectomy sepsis.<sup>45</sup>

## REFERENCES

- Shackford SR, Sise MJ, Virgilio RW, Peters RM. Evaluation of splenorhaphy: a grading system for splenic trauma. *J Trauma*. 1981; 21:538–542.
- Pachter HL, Hofstetter SR, Spencer FC. Evolving concepts in splenic surgery. *Ann Surg*. 1981;194:262–269.
- Millikan JS, Moore EE, Moore GE, Stevens RE. Alternatives to splenectomy in adults after trauma. *Am J Surg*. 1982;144:711–716.
- Wesson DE, Filler RM, Ein SH, Shandling B, Simpson JS, Stephens CA. Ruptured spleen—when to operate? *J Pediatr Surg*. 1981; 16:324–326.
- Haller JA, Papa P, Drugas G, Colombani P. Nonoperative management of solid organ injuries in children. *Ann Surg*. 1994; 219:625–631.
- Coburn MC, Pfeifer J, DeLuca FG. Nonoperative management of splenic and hepatic trauma in the multiply injured pediatric and adolescent patient. *Arch Surg*. 1995;130:332–338.
- Malangoni MA, Levine AW, Droege EA, Aprahamian C, Condon RE. Management of injury to the spleen in adults. *Ann Surg*. 1994; 200:702–705.
- Mahon PA, Sutton JE. Nonoperative management of adult splenic injury due to blunt trauma: a warning. *Am J Surg*. 1985;149:716–721.
- Mucha P, Daly RC, Farnell MC. Selective management of blunt splenic trauma. *J Trauma*. 1986;26:970–979.
- Nallathambi MN, Ivatury RR, Wapnir I, Rohman M, Stahl WM. Nonoperative management versus early operation for blunt splenic trauma in adults. *Surg Gynecol Obstet*. 1988;166:252–258.
- Traub AC, Perry JF. Injuries associated with splenic trauma. *J Trauma*. 1981;21:840–846.
- Livingston CD, Sirinek KR, Levine BA, Aust JB. Traumatic splenic injury. *Arch Surg*. 1982;117:670–674.
- Buckman RF, Piano G, Dunham M, Soutter I, Ramzy A, Militello PR. Major bowel and diaphragmatic injuries associated with blunt spleen or liver rupture. *J Trauma*. 1988;28:1317–1320.
- Cogbill TH, Moore EE, Jurkovich GJ, et al. Nonoperative management of blunt splenic trauma: a multicenter experience. *J Trauma*. 1989;29:1312–1317.
- Archer LP, Rogers FB, Shackford SR. Selective nonoperative management of liver and spleen injuries in neurologically impaired adult patients. *Arch Surg*. 1996;131:309–315.
- Pachter HL, Guth AA, Hofstetter SR, Spencer FC. Changing patterns in the management of splenic trauma. *Ann Surg*. 1998;227:708–719.
- Weigelt JA, Kingman RG. Complications of negative laparotomy for trauma. *Am J Surg*. 1988;156:544–547.
- Renz BM, Feliciano DV. Unnecessary laparotomies for trauma: a prospective study of morbidity. *J Trauma*. 1995;38:350–356.
- Ross SE, Dragon GM, O'Malley KF, Rehm CG. Morbidity of negative celiotomy in trauma. *Injury*. 1995;26:393–394.
- Luna GK, Dellinger EP. Nonoperative observation therapy for splenic injuries: a safe therapeutic option? *Am J Surg*. 1987; 153:462–468.
- Cocanour CS, Moore FA, Ware DN, Marvin RG, Duke JH. Age should not be a consideration for nonoperative management of blunt splenic injury. *J Trauma*. 2000;48:606–612.
- Smith JS, Cooney RN, Mucha P. Nonoperative management of the ruptured spleen: a revalidation of criteria. *Surgery*. 1996;120:745–751.
- Konstantakos AK, Barnoski AL, Plaisier BR, Yowler CJ, Fallon WF Jr, Malangoni MA. Optimizing the management of blunt splenic injury in adults and children. *Surgery*. 1999;126:805–813.
- Peitzman AB, Heil B, Rivera L, et al. Blunt Splenic injury in adults: Multi-institutional Study of the Eastern Association for the Surgery of Trauma. *J Trauma*. 2000;49:187–189.



25. Selifani SJA, Shaftan GW, Scalea TM, et al. Nonoperative salvage of computed tomography-diagnosed splenic injuries: utilization of angiography for triage and embolization for hemostasis. *J Trauma*. 1995;39:818–827.
26. Davis KA, Fabian TC, Croce MA, Gavin TJ. Improved success in nonoperative management of blunt splenic injuries: embolization of splenic artery pseudoaneurysms. *J Trauma*. 1998;44:1008–1012.
27. Haan J, Scott J, Boyd-Kranis RL, Ho S, Kramer M, Scalea TM. Admission angiography for blunt splenic injury: advantages and pitfalls. *J Trauma*. 2001;51:1161–1165.
28. Haan JM, Biffl W, Knudson MM, et al. Splenic embolization revisited: a multicenter review. *J Trauma*. 2004;56:542–547.
29. Dent D, Alsabrook G, Erickson BA, et al. Blunt splenic injuries: high nonoperative management rate can be achieved with selective embolization. *J Trauma*. 2004;56:1063–1067.
30. Wahl WL, Ahrns KS, Chen S, Hemmilla MR, Rowe SA, Arbabi S. Blunt splenic injury: operation versus angiographic embolization. *Surgery*. 2004;136:891–899.
31. Haan JM, Bochicchio GV, Kramer N, Scalea TM. Nonoperative management of blunt splenic injury: a 5-year experience. *J Trauma*. 2005;58:492–498.
32. Rajani RR, Claridge JA, Yowler CH, et al. Improved outcome of adult blunt splenic injury: a cohort analysis. *Surgery*. 2006;140:625–632.
33. Weinberg JA, Magnotti LJ, Croce MA, Edwards NM, Fabian TC. The utility of serial computed tomography imaging of blunt splenic injury: still worth a second look? *J Trauma*. 2007;62:1143–1148.
34. Harbrecht BG, Ko SH, Watson GA, Forsythe RM, Rosengart MR, Peitzman AB. Angiography for blunt splenic trauma does not improve the success rate of nonoperative management. *J Trauma*. 2007;63:44–49.
35. Nix JA, Costanza M, Daley BJ, Powell MA, Enderson BL. Outcome of the current management of splenic injuries. *J Trauma*. 2001; 50:835–842.
36. Meredith JW, Young JS, Bowling J, Roboussin D. Nonoperative management of blunt hepatic trauma: the exception or the rule? *J Trauma*. 1994;36:529–535.
37. Moore FA, McKinley BA, Moore EE, et al. Inflammation and the Host Response to Injury, a large-scale collaborative project: patient-oriented research core—standard operating procedures for clinical care. III. Guidelines for shock resuscitation. *J Trauma*. 2006;61:82–89.
38. Allen GS, Moore FA, Cox CS, Mehall JR, Duke JH. Delayed diagnosis of blunt duodenal injury: an avoidable complication. *J Am Coll Surg*. 1998;187:393–399.
39. Kohn JS, Clark D, Isler RJ, Pope CF. Is computed tomographic grading of splenic injury useful in nonsurgical management of blunt trauma. *J Trauma*. 1994;36:385–389.
40. Moore EE, Cogbill TH, Jurkovich GJ, Shackford SR, Malangoni MA, Champion HR. Organ injury scaling: spleen and liver. *J Trauma*. 1995;38:323–324.
41. Marmery H, Shanmuganathan K, Alexander MT, Mirvis SE. Optimization of selection for nonoperative management of blunt splenic injury: comparison of MDCT grading system. *AJR Am J Roentgenol*. 2007;89:1421–1427.
42. Hann JM, Matmery H, Shanmuganathan K, Mirvis SE, Scalea TM. Experience with splenic main coil embolization and significance of new or persistent Pseudoaneurysm: Reembolize, operate, or observe. *J Trauma*. 2007;63:615–619.
43. Cocanour CS, Moore FA, Ware DN, Marvin RG, Clark JM, Duke JH. Delayed complications of nonoperative management of blunt splenic trauma. *Arch Surg*. 1998;133:619–625.
44. Crawford RS, Tabbara M, Sheridan R, Spaniolas K, Velmahos GC. Early discharge after nonoperative management for splenic injuries: increased patient risk caused by late failure? *Surgery*. 2007;142:337–342.
45. Leemans R, Snijder JA, Smit J, et al. Immune response capacity after human splenic autotransplantation: restoration of response to individual vaccine subtypes. *Ann Surg*. 1999;229:279–285.