

Deep Impact of Ultrasound in the Intensive Care Unit

The “ICU-sound” Protocol

Emilpaolo Manno, M.D.,* Mauro Navarra, M.D.,† Luciana Faccio, M.D.,† Mohsen Motevallian, M.D.,† Luca Bertolaccini, M.D., Ph.D.,‡ Abdou Mfochivè, M.D.,† Marco Pesce, M.D.,† Andrea Evangelista, M.S.§

ABSTRACT

Background: Ultrasound can influence the diagnosis and impact the treatment plan in critical patients. The aim of this study was to determine whether, without encountering major environment- or patient-related limitations, ultrasound examination under a critical care ultrasonography protocol can be performed to detect occult anomalies, to prompt urgent changes in therapy or induce further testing or interventions, and to confirm or modify diagnosis.

Methods: One hundred and twenty-five consecutive patients admitted to a general intensive care unit were assessed under a critical care ultrasonography protocol, and the data were analyzed prospectively. Systematic ultrasound examination of the optic nerve, thorax, heart, abdomen, and venous system was performed at the bedside.

Results: Environmental conditions hampered the examination slightly in 101/125 patients (80.8%), moderately in 20/125 patients (16%), and strongly in 4/125 patients (3.2%). Ultrasonographic findings modified the admitting diagnosis in 32/125 patients (25.6%), confirmed it in 73/125 patients (58.4%), were not effective in confirming or modifying it in 17/125 patients (13.6%), and missed it in 3/125 patients (2.4%). Ultrasonographic findings prompted

What We Already Know about This Topic

- Ultrasound examination is now being utilized in the intensive care unit to detect lung abnormalities and recruitment

What This Article Tells Us That Is New

- Transthoracic ultrasound examination can be used to diagnose a multitude of abnormalities, helped modify admitting diagnoses in 26% of patients, led to changes in medical therapy in 18% of patients, and prompted invasive procedures in 22% of patients

further testing in 23/125 patients (18.4%), led to changes in medical therapy in 22/125 patients (17.6%), and to invasive procedures in 27/125 patients (21.6%).

Conclusions: In this series of patients consecutively admitted to an intensive care unit, ultrasound examination revealed a high prevalence of unsuspected clinical abnormalities, with the highest number of new ultrasound abnormalities detected in patients with septic shock. As part of rapid global assessment of the patient on admission, our ultrasound protocol holds potential for improving healthcare quality.

RAPID and accurate diagnosis and treatment are crucial and problematic for patients admitted to an intensive care unit (ICU). The inaccuracy of physical examination at admission to the ICU has been extensively reported. Different diagnostic imaging modalities have been developed, but most lack sensitivity, availability, and portability. Diagnostic accuracy can be increased when a brief echocardiographic study is added to extend the physical examination.¹

Ultrasonography has grown rapidly and gained widespread acceptance. In a recent study, up to 36% of patients

* Head of Emergency Department and Intensive Care Unit, † Staff Anesthesiologist, Intensive Care Unit, Maria Vittoria Hospital, Torino, Italy. ‡ Thoracic Surgeon, Thoracic Surgery Unit, S. Croce e Carle Hospital, Cuneo, Italy. § Researcher, Unit of Cancer Epidemiology, San Giovanni Battista Hospital, Torino, Italy.

Received from the Emergency Department and Intensive Care Unit, Maria Vittoria Hospital, Torino, Italy. Submitted for publication June 9, 2011. Accepted for publication June 6, 2012. Support was provided solely from institutional and/or departmental sources.

Address correspondence to Dr. Manno: Via Ruatta, 34, 10040 Rubiana, Torino, Italy. manno@aslto2.it. Information on purchasing reprints may be found at www.anesthesiology.org or on the masthead page at the beginning of this issue. ANESTHESIOLOGY's articles are made freely accessible to all readers, for personal use only, 6 months from the cover date of the issue.

Copyright © 2012, the American Society of Anesthesiologists, Inc. Lippincott Williams & Wilkins. Anesthesiology 2012; 117:801-9

◆ This article is accompanied by an Editorial View. Please see: Pelosi P, Corradi F: Ultrasonography in the intensive care unit: “Looking at the world through colored glasses.” ANESTHESIOLOGY 2012; 117:696-8.

admitted to an ICU with a noncardiac diagnosis had one or more occult cardiac abnormalities.² ICU patients often present with thoracic and abdominal pathologies, making ultrasound examination essential for prompt diagnosis and treatment and to prevent the patient's conditions from deteriorating or resulting in death.³⁻⁵ Safe, accurate, rapid, and repeatable at the bedside, the use of ultrasound in the ICU has been extensively validated as it provides data that may not be obtained with other routine methods.⁶ Furthermore, because of the patient's critical condition, diagnostic accuracy is essential at ICU admittance.

The "ICU-sound" protocol was developed for a rapid global assessment, which linked real-time ultrasonographic evaluation with clinical data. This study was designed to test the hypothesis that a head-to-toe ultrasound evaluation at ICU admittance could increase diagnostic accuracy. A prospective study was undertaken to investigate whether the protocol can be performed without encountering major environment- or patient-related limitations, detect occult anomalies, prompt urgent changes in therapy or further testing, and confirm or modify the admitting diagnosis.

Materials and Methods

Between March 2009 and January 2010, a total of 262 consecutive patients were admitted to the general ICU of Maria Vittoria Hospital, Torino, Italy. Excluded from the analysis were 121 patients who left the ICU alive within 48 h (usually postoperative or drug-poisoning patients); seven others because of lack of consent; and nine others because of patient-related conditions that strongly hampered ultrasound examination. The final data analysis was performed on 125 patients. The study design was approved by the ethical review board of our institution (Ethical Committee ASL TO2, Turin, Italy) and written informed consent was obtained. The ICU has six beds and the ICU staff consists of six physicians skilled in ultrasound.

The admitting diagnosis was made by the attending physician under the supervision of the senior physician and established on the basis of the diagnosis received from the department of referral, history taking, clinical examination, and laboratory and imaging findings. The admitting diagnosis was made without beside ultrasonographic evaluation.

Within 12 h of ICU admission, all patients underwent head-to-toe ultrasound examination performed by a different attending physician (not the same one as at admittance) under the "ICU-sound" protocol developed at our institution. Table 1 reports the criteria for defining ultrasound-induced changes, confirmation, wrong evaluation, and lack of confirmation of the admitting diagnosis.

The decision to change the admitting diagnosis or medical therapy or to perform invasive procedures was taken by the senior physician jointly with the ICU director, considering or not a gold standard. Not included in the analysis were the data from a second and third examination per-

Table 1. Criteria to Define Ultrasound-induced Modification, Confirmation, Wrong Evaluation, and Lack of Confirmation of Admitting Diagnosis

Definitions	Criteria
Ultrasound-induced modification of admitting diagnosis	<ul style="list-style-type: none"> a) Ultrasound evidence of an aetiological diagnosis (unknown) upon a generic organ failure b) Ultrasound allows a different aetiological diagnosis in comparison with the aetiological admitting diagnosis
Ultrasound-induced confirmation of admitting diagnosis	Ultrasound confirms the aetiological admitting diagnosis
Ultrasound-induced wrong evaluation of diagnosis	<ul style="list-style-type: none"> a) Ultrasound-based aetiological diagnosis is not confirmed by gold standard b) Ultrasound missed aetiological diagnosis evidenced by gold standard
Lack of confirmation of diagnosis by ultrasound	Ultrasound is not effective in confirming or modifying aetiological diagnosis

formed by the attending physician according to changes in clinical conditions.

At the time of ICU admission, the severity of the patient's condition was graded according to the new Simplified Acute Physiology Score (SAPS II).⁷ A report form completed for each examination at the patient's bedside immediately after sonography included items on environment- or patient-related limitations, ultrasound examination, and epidemiologic and clinical data on paper-based case report forms. The two ICU ultrasound systems were a CX50 (Philips Healthcare, Andover, MA) equipped with a 3–12 MHz linear probe, a 1–5 MHz sector probe, and a 1–5 MHz convex probe, and a Philips EnVisor C HD (Philips Healthcare) equipped a 5–8 MHz micro-convex probe, a 2–4 MHz sector probe, and a 2–5 MHz convex probe.

The ICU-sound protocol comprises the following ultrasound examinations:

Optic nerve. The optic nerve sheath diameter is measured 3 mm posterior to the papilla. This is done only in comatose or deeply sedated patients.

Chest. Six ultrasound areas are examined: anterior, lateral, and posterolateral views in the upper and lower thoracic walls on each side. The probe is moved ventral-to-dorsal on longitudinal and axial scans.

Heart. Basic views necessary to perform a goal-directed transthoracic echocardiography are used: parasternal long-

Table 2. Specific Diagnostic Challenge and Critical Ultrasound Findings Prospectively Defined in ICU-sound Protocol

Clinical Diagnosis	Ultrasound Finding
Neurologic examination	—
Intracranial hypertension	Optic nerve sheath diameter more than 5 mm
Thoracic examination	—
Pneumothorax	Absence of “lung sliding,” absence of B-lines, detection of the “lung point”
Lung consolidation	Hypoechoic area with an air bronchogram: static or dynamic
Cardiogenic pulmonary edema	More than 3 B-lines/examined area; extended from the lung bases to the medium and superior fields, bilaterally, symmetrically, without pleural line abnormalities
ARDS/ALI	Nonhomogeneous B-line distribution (more than 3 B-lines/examined area); presence of spared areas and pleural line abnormalities; subpleural consolidations
Pleural effusion	Echo-poor or echo-free space between the pleura visceralis and parietal pleura
Asthma/COPD/Normal lung aeration	Bilateral A lines with lung sliding
Heart examination	—
Valvular disease	Moderate/severe valvular insufficiency/stenosis
EF <35%	EF less than 35%
LV, LA dilatation	LA more than 5 cm, LV more than 6 cm
Dilated RV, RA with overload pattern	—
Pericardial effusion	Moderate/severe pericardial effusion more than 2 cm
Valve vegetation	Valve vegetation
LVH	—
Abnormal abdomen examination	—
Peritoneal effusion	Anechogenic or moderately echogenic pattern
Cholecystitis	Gallbladder distension, pericholecystic fluid, gallbladder wall more than 3.5 mm, Echo–Murphy sign
Hydronephrosis	Dilatated pelvis and collecting system, hypoechoic area in the kidney hilum
Parenchymal abnormalities (pancreas, spleen liver, kidney, bladder)	Parenchymal abnormalities, bladder assessment for retention
Abnormal venous system examination	—
DVT positive vein compression test	Positive vein compression test

ALI = acute lung injury; ARDS = adult respiratory distress syndrome; COPD = chronic obstructive pulmonary disease; DVT = deep vein thrombosis; EF = ejection fraction; ICU = intensive care unit; LA = left atrium; LV = left ventricle; LVH = left ventricular hypertrophy; RA = right atrium; RV = right ventricle.

axis and short-axis views, apical five-chamber, four-chamber and two-chamber views, and subcostal views. Transesophageal echocardiography is not used.

Abdomen. The probe is moved over six abdominal areas. The areas are epigastrium: longitudinal view; right hypochondrium: axial, longitudinal and coronal views; mesogastric: axial and longitudinal views; left hypochondrium: coronal; hypogastric: longitudinal; and right iliac fossa: axial view.

Venous system. Lower limb (right and left femoral and popliteal veins), upper limb (right and left basilica, cephalic and axillary veins), neck vessels (right and left jugular veins), mild compression maneuver.

On completion of each examination, the transducer is cleaned with a germicidal detergent. For the purposes of this study, specific diagnostic challenges and critical abnormalities were prospectively defined (table 2). Findings without a direct impact on diagnosis and/or therapy (renal or hepatic cysts, gallstones, prostatic hypertrophy, hepatic steatosis) were not taken into account.

Statistical Analysis

The association between ICU mortality and number of pathologic findings was evaluated using logistic regression models. Patients were classified into three groups according to the number of pathologic findings: none, only 1, 2, or more. Crude and SAPS-adjusted odds ratios (ORs) were reported along with its 95% CI. In the estimation of SAPS-adjusted ORs, the SAPS score was included as continuous variable in the logistic model. Cohen’s κ was applied to measure agreement between pairs of readers and averaged over all pairs to evaluate overall agreement.⁸ Statistical analysis was carried out with R 2.15.0 (R Foundation for Statistical Computing, Vienna, Austria).

Results

The study population was 125 patients. Table 3 reports patient demographics; table 4 reports the distribution of admitting diagnosis and SAPS II scores. In nine cases, patient-

Table 3. Patient Demographics

Characteristics	Total Patients (n = 125)	Ultrasound Abnormalities	
		With (n = 107)	Without (n = 18)
Age*	64	—	—
Age range (yr)	27–88	27–88	30–84
Gender	—	—	—
Male	75	62	13
Female	50	45	5

* Value given as mean.

related conditions (obesity, subcutaneous emphysema, bandages, digestive gas) strongly hampered the examination in some areas, so that the protocol could not be performed entirely; these cases were excluded from the study. Environment-related limitations were defined as brightness of room illumination, space around the patient, noise, and isolation. Examinations were carried out under 0–1 limiting conditions resulting in “good or slightly impaired quality of the examination” in 101/125 (80.8%) cases, under 2 limiting conditions resulting in “moderately impaired quality” in 20/125 (16%) cases, and under 3–4 limiting conditions resulting in “impaired quality” but still possible in 4/125 (3.2%) cases. The time needed to complete scanning ranged from 17 to 54 min (median, 19.5 min).

To simplify data collection, the ultrasound findings were subdivided in three categories: new pathologic findings (previously unknown abnormalities); pathologic findings (already known abnormalities); and normal findings. All new pathologic findings were downloaded and stored on a server. This was done to allow us to later retrieve the findings and discuss difficult cases and images with colleagues.

Examinations showed “normal” findings in 18/125 patients (14.4%) and ultrasound abnormalities in 107/125 patients

(85.6%). Table 5 reports the distribution of the abnormal findings. In the group of 107 patients with ultrasound abnormalities, examination revealed 254 pathologic finding(s), 136 of which were classified as “new pathologic finding(s).” It is clear that the same patient could have had more than one pathologic finding. Table 6 illustrates the number of pathologic findings observed and the related ICU mortality.

Ultrasound examination confirmed the admitting diagnosis in 73/125 cases (58.4%), modified it in 32/125 cases (25.6%), was ineffective in confirming or modifying it in 17/125 cases (13.6%), and missed it in 3/125 cases (2.4%).

The ultrasonographic findings prompted: 1) further testing in 23/125 patients (18.4%, 95% CI: 12.0–26.3%); 2) changes in medical therapy in 22/125 patients (17.6%, 95% CI: 11.4–25.4%; and 3) invasive procedures in 27/125 patients (21.6%, 95% CI: 14.7–29.8%). The changes in medical therapy in the 22 patients were subdivided into: administration of a thrombolytic drug (n = 1); increase in dosage of low-molecular-weight heparin (n = 2); administration of nitric oxide (dilated right ventricle, right atrial with overload pattern, severe tricuspid regurgitation in patients with the adult respiratory distress syndrome) (n = 3); administration of an inotropic drug (n = 6); administration of a vasoactive drug (n = 4); diuretic therapy (n = 3); and antibiotic therapy (n = 3). Subsequent to ultrasound examination, 27 invasive procedures were performed: thoracic drainage (n = 23); pericardiocentesis (n = 1); paracentesis (n = 1); and emergency bronchoscopy (n = 2). The procedures were carried out under ultrasound guidance, and no procedure-related complications occurred.

In 61/125 cases (48.8%), the senior physician ordered a gold standard procedure (computed tomography, magnetic resonance imaging, transesophageal echocardiography) that confirmed the ultrasonographic findings. Ultrasound examination missed abnormalities in three cases: Pancreatitis (n = 1) and pneumonia (n = 1) were demonstrated by computed

Table 4. Study Population Stratified According to Admitting Diagnosis, SAPS II Score at Admission, and Number of New Ultrasound Abnormalities

Diagnostic Group	No. of Patients	%	SAPS II Score* (95% CI)	No. of New Ultrasonographic Abnormalities
Cardiac arrest	14	11.2	52 (43–60)	19
COPD-Asthma	16	12.8	39 (32–46)	13
Trauma	9	7.2	29 (19–38)	3
Acute Cardiac Decompensation	27	21.6	40 (36–45)	34
ARDS/Pneumonia	11	8.8	42 (32–55)	13
Postoperative complications	14	11.2	40 (33–47)	14
Meningo-encephalitis	5	4	42 (35–49)	2
Neurologic disease	5	4	36 (18–55)	2
Septic shock	18	14.4	47 (39–55)	28
Other	6	4.8	42 (34–50)	8
Total/average	125	—	41 (39–44)	136

* Score at admission; values given as mean.

ARDS = adult respiratory distress syndrome; COPD = chronic obstructive pulmonary disease; SAPS II = Simplified Acute Physiology Score.

Table 5. Distribution of Pathological Findings on Ultrasound Examination and Distribution of Changes in Medical Therapy and Invasive Procedures

Findings	Findings, No. (%)	New Findings, No. (%)	Changes in Medical Therapy, No. of Cases (%)	Invasive Procedures, No. of Cases (%)
Neurologic Abnormalities		—	—	—
Intracranial hypertension	8 (3.1)	6 (4.4)	—	—
Thoracic Abnormalities	—	—	—	—
Pneumothorax	7 (2.7)	3 (2.2)	—	3 (2.4)
Lung consolidation	38 (14.9)	23 (16.9)	3 (2.4)	2 (1.6)
Cardiogenic pulmonary edema	10 (3.9)	4 (2.9)	3 (2.4)	—
ARDS/ALI	4 (1.5)	—	—	—
Pleural effusion	35 (13.7)	25 (18.3)	—	20 (16)
Cardiac Abnormalities	—	—	—	—
Valvular disease	30 (11.8)	17 (12.5)	—	—
EF 35% or less	35 (13.7)	15 (11.0)	6 (4.8)	—
LV, LA dilatation	16 (6.3)	3 (2.2)	—	—
Pericardial effusion	10 (3.9)	6 (4.4)	—	1 (0.8)
RA thrombus	1 (0.3)	1 (0.7)	1 (0.8)	—
LVH	24 (9.4)	6 (4.4)	—	—
Dilated RV, RA with overload pattern	6 (2.36)	4 (2.94)	3 (2.4)	—
Valve vegetations	1 (0.3)	1 (0.7)	1 (0.8)	—
Abdominal Abnormalities	—	—	—	—
Peritoneal effusion	11 (4.3)	9 (6.6)	1 (0.8)	1 (0.8)
Cholecystitis	3 (1.1)	2 (1.4)	2 (1.6)	—
Hydronephrosis	3 (1.1)	3 (2.2)	—	—
Parenchymal abnormalities hepatosplenomegaly, end stage kidney, pancreatitis	8 (3.1)	6 (4.4)	—	—
Venous System Abnormalities	—	—	—	—
DVT	4 (1.5)	2 (1.4)	2 (1.6)	—
Total	254	136	22 (17.6)	27 (21.6)

ALI = acute lung injury; ARDS = adult respiratory distress syndrome; DVT = deep vein thrombosis; EF = ejection fraction; LA = left atrium; LV = left ventricle; LVH = left ventricular hypertrophy; RA = right atrium; RV = right ventricle.

tomography, and transesophageal echocardiography revealed a severe aortic insufficiency ($n = 1$).

ICU mortality was higher, but not statistically significant, in patients with two or more pathologic findings respect to patients without any findings (SAPS-adjusted OR 2.49, 95% CI: 0.79–7.85) (table 6). The level of agreement between two sets of dichotomous findings was compared using Cohen's κ . We created a crosstabs table to compare the ultrasonographic findings recorded by the two physicians. The average κ coefficient of agreement in interpretation was 0.69 for all readers; the κ values ranged from 0.52 to 0.86, confirming good agreement among all observers.

Discussion

Our study is unique in that it is a surveillance study of 125 consecutive patients whose evaluation entailed a global as-

essment encompassing clinical and ultrasound examination. Unlike previous works,^{2–6} it was performed to evaluate a protocol for head-to-toe ultrasound examination performed by a team of ICU physicians experienced in ultrasonography. Real-time ultrasound evaluation (within 12 h of admission) was done by the attending physician. The approach is based on the assumption that intensive care physicians with enough expertise can interpret sonographic images.

Ultrasound training is not mandatory for ICU physicians in Italy, although proposals for graded competence have been advanced.^{9–11} Since 2000, the Society for Academic Emergency Medicine guidelines for physician training in emergency ultrasonography¹² have informed the continuing medical education program of our ICU physicians. During their time in the course, physicians are required to perform 150 practice sections, including 60 heart, 10 chest, 60

Table 6. ICU Mortality According to Number of Pathological Findings

Pathological Findings	No. (%)	ICU Mortality, No. (%)	OR (95% CI)	adjOR* (95% CI)
None	45 (36.0%)	9 (25.7%)	1 (Reference)	1 (Reference)
Only 1	41 (32.8%)	9 (25.7%)	1.13 (0.4–3.18)	0.98 (0.28–3.38)
2 or more	39 (31.2%)	17 (48.6%)	3.09 (1.18–8.13)	2.49 (0.79–7.85)

* SAPS II-adjusted odds ratios.

ICU = intensive care unit; OR = odds ratio; SAPS II = Simplified Acute Physiology Score.

abdomen, and 20 peripheral vein ultrasound examinations. After the course, the physicians receive 1 yr of tutored instruction.

Drawn up in 2008, the ICU-sound protocol was tested for 6 months before entering daily clinical practice. Our data suggest that the protocol is not excessively time-consuming: a mean duration of 19.5 min to complete the scan is acceptable considering the protocol's complexity. Patient- and environment-related ultrasonography limitations had little influence on the majority of the ultrasound examinations in this study.

We used optic nerve sonography as an additional noninvasive diagnostic tool to detect increased intracranial pressure preceding emergency computed tomography or the decision to start invasive monitoring of intracranial pressure.^{13–15} Ultrasound examination revealed new findings of optic nerve sheath enlargement in six cases, in all of which computed tomography showed unknown intracranial hypertension, demonstrating the importance of this easy-to-perform ultrasound evaluation at admittance to a general ICU.

Two cases of unknown deep venous thrombosis were identified, one an internal jugular vein thrombosis (fig. 1). Upper extremity venous thrombosis is thought to be quite rare, but a recent report found that 18% of all cases involve upper extremity thrombi.¹⁶ Patients in the ICU setting are especially vulnerable to developing upper extremity thrombosis, and the clinical symptoms associated with an upper extremity clot are frequently absent because of the extensive collateral network.^{17,18} A combined strategy using echocardiography and venous ultrasonography is a reliable method for diagnosing pulmonary embolism at the bedside.^{19,20}

Pleural effusion is often encountered in ICU patients; the diagnosis relies mostly on an anteroposterior chest radiograph obtained at the bedside. Pleural ultrasonography, an alternative imaging modality, has been validated against chest computed tomography, the accepted reference for di-

agnostic methods to identify pleural disease.^{21,22} The prevalence of significant pleural effusions in a medical ICU varies widely from 8.4 to 62%.^{23,24}

In our study, effusions (small effusions less than 200 ml were not considered) were found in 35/125 patients (28%), 20 (57.1%) of whom underwent drainage and thoracentesis. The estimated drainage volume was obtained using the formula proposed by Balik *et al.*²⁵ It has been recently shown, however, that this formula can underestimate the volume,²⁶ whereas a multiplane approach can increase the accuracy of quantifying small and moderate pleural effusion. Although more time-consuming (10 min), an accurate evaluation of effusion volume is a critical element in deciding whether to perform thoracentesis. And it becomes even more relevant when weaning is considered, because drainage may reduce the work of breathing and increase respiratory muscle efficiency.²⁷

The decision to drain was based on our clinical practice (reduced chest wall compliance, difficult weaning, refractory hypodynamic circulatory states) or when ultrasound suggested an infectious effusion (homogeneous echogenicity, septation, fibrin strands, nodular pleural changes). Pleural effusion can cause dissociation between effective preload and cardiac filling pressures. Drainage may be effective in patients with refractory hypodynamic circulatory states, particularly when there is evidence for diastolic chamber collapse.²⁸

Ultrasound examination was effective in evidencing the presence of anterior pneumothorax not detected by supine anteroposterior chest radiography (three cases). This finding holds clinical relevance, because during positive pressure ventilation a small pneumothorax may progress and cause hemodynamic instability. Ultrasound has proved to be more sensitive than anteroposterior chest radiography in the diagnosis of pneumothorax^{29,30} and can decrease the need for computed tomography for the diagnosis of occult pneumothorax.³¹ Lower lobe parenchymal consolidation without air bronchogram visualization can be difficult to distinguish from pleural effusion on an anteroposterior chest radiograph.³² Ultrasonography showing consolidation (with or without pleural effusion) can help in avoiding a possible mistake because of a misread chest radiograph (fig. 2).

Lung sonography is a useful aid in differentiating cardiogenic respiratory failure from acute airflow limitation, consolidation, pleural effusion, or pulmonary embolism.^{33–35} In our study, the diagnostic efficacy of lung ultrasound to differentiate dyspneic patients is well represented. Lung ultrasound pointed out 55 new findings, enabling us to differentiate the etiologic diagnosis in patients with a generic admitting diagnosis of acute respiratory insufficiency. Combining the data from lung sonography and echocardiography can enhance the diagnostic accuracy in differentiating respiratory insufficiency (fig. 3).

In a previous study, transthoracic echocardiography performed by intensivists provided new information and

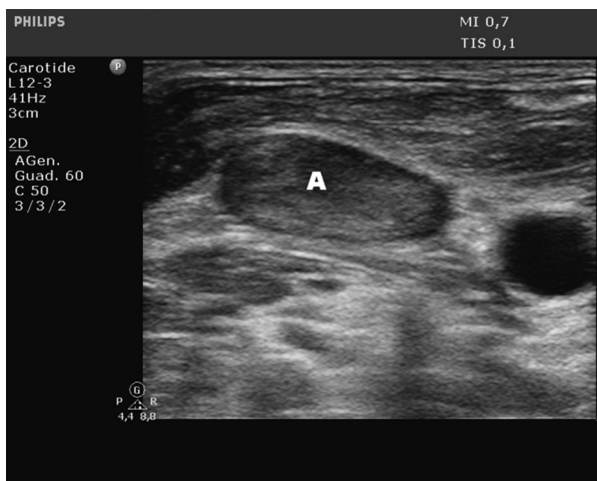


Fig. 1. Internal jugular vein thrombosis (A) in a young patient with varicella pneumoniae and adult respiratory distress syndrome. Thrombophilia workup revealed anti- $\beta 2$ glycoprotein I positivity.

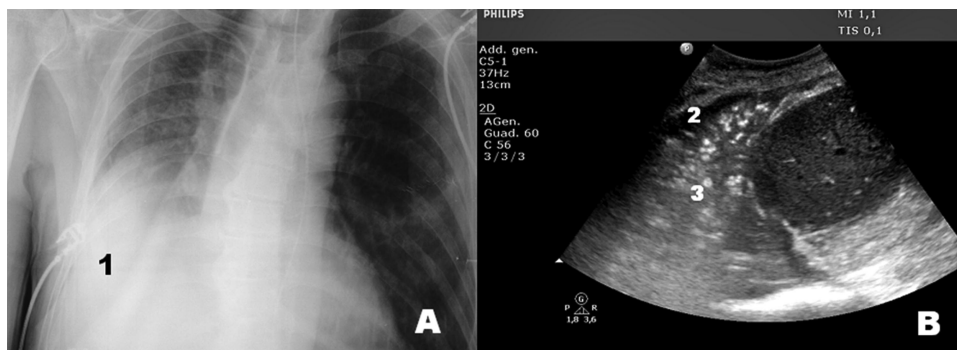


Fig. 2. (A) Chest radiograph suggested a pleural effusion (1); (B) ultrasonography evidenced a small pleural effusion (2) and an important lung consolidation (3).

changed management in 37% of critical patients and added useful information to an additional 47% of patients, but did not alter immediate treatment.³⁶ In our study, echocardiography revealed 53 new findings, leading to changes in therapy in 11/125 patients. These data confirm the importance of transthoracic echocardiography in ICU patients. Abdominal examination evidenced 20 new pathologic findings and induced changes in therapy in 3/125 cases. The presence of the classic signs³⁷ of acute acalculous cholecystitis at ultrasound examination, together with clinical data, enabled us to identify the origin of sepsis of unknown etiology (fig. 4).

In our study, new ultrasound abnormalities were most often detected in patients with septic shock, followed by those with acute cardiac decompensation. This is not surprising, as these patients have multiple organ failure. ICU mortality was higher, but not statistically significant, in patients with two or more pathologic findings compared with patients without any findings. Mortality generally depends on the specific type of the most life-threatening abnormality, along with many other factors unrelated to ultrasound findings. Of note is that patients with no ultrasonographic pathologic findings had a better prognosis.

We plan to extend the ICU-sound protocol to include other diagnostic tools: transcranial Doppler and positive end-expiratory pressure-induced lung recruitment. Recent reports have shown, in fact, that lung re-aeration can be assessed by ultra-

sound. It is rapid and repeatable at the bedside, does not require sedation and paralysis, and can be used to analyze dependent and not-dependent lung regions. Patients with acute lung injury, the adult respiratory distress syndrome, and pulmonary edema may benefit from ultrasound monitoring of positive end-expiratory pressure-induced re-aeration;^{38–40} however, a limitation is that lung hyperinflation cannot be assessed.

Study Limitations

There is a potential for bias, as the operators in this study were not blinded to the patient's clinical picture, which is difficult to entirely eliminate in any use of ultrasound. The study relied only on transthoracic echocardiography; therefore, the true prevalence of cardiac ultrasound abnormalities may have been underestimated. Also, the prevalence of pleural effusion may have been underestimated with the use of a formula, which has been shown inadequate to quantify small and moderate effusions. An evaluation of the usefulness of a head-to-toe *versus* a focused examination was beyond the scope of this study.

The major finding of this study is the discovery of a high prevalence of unsuspected clinical abnormalities in ICU patients. Ultrasound examination permitted us to modify the diagnosis and to improve the treatment, with prompt changes in therapeutic strategy. Patient- and environment-related sonogra-

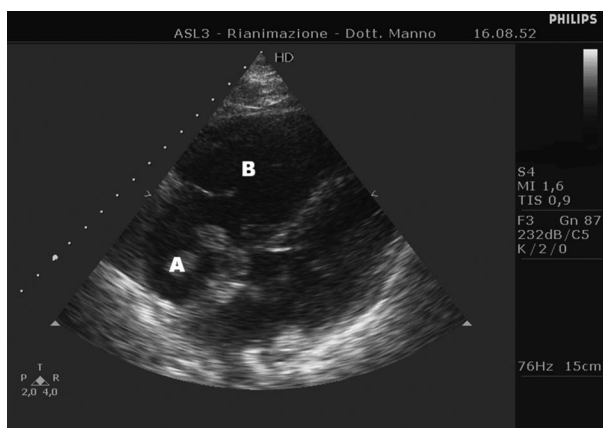


Fig. 3. Image of the right atrium clot (A), dilated right ventricle (B), and small-sized left ventricle in apical 4-chamber view.

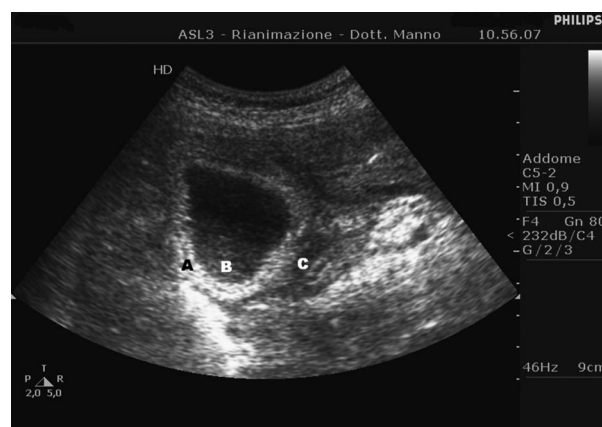


Fig. 4. Classic signs of acute acalculous cholecystitis: enlarged gallbladder, wall thickening (A), biliary sludge (B), and perivescicular fluid collection (C).

phy limitations had little influence on the majority of the examinations. The test can be performed by the attending ICU physician, with minimal risk of overuse or misinterpretation. Moreover, ultrasound use in the ICU could be optimized by making ultrasonography a routine part of intensive care training during residency.⁴¹ In experienced hands, rapid global assessment of critical patients at ICU admittance under this ultrasound protocol holds potential for improving healthcare quality.

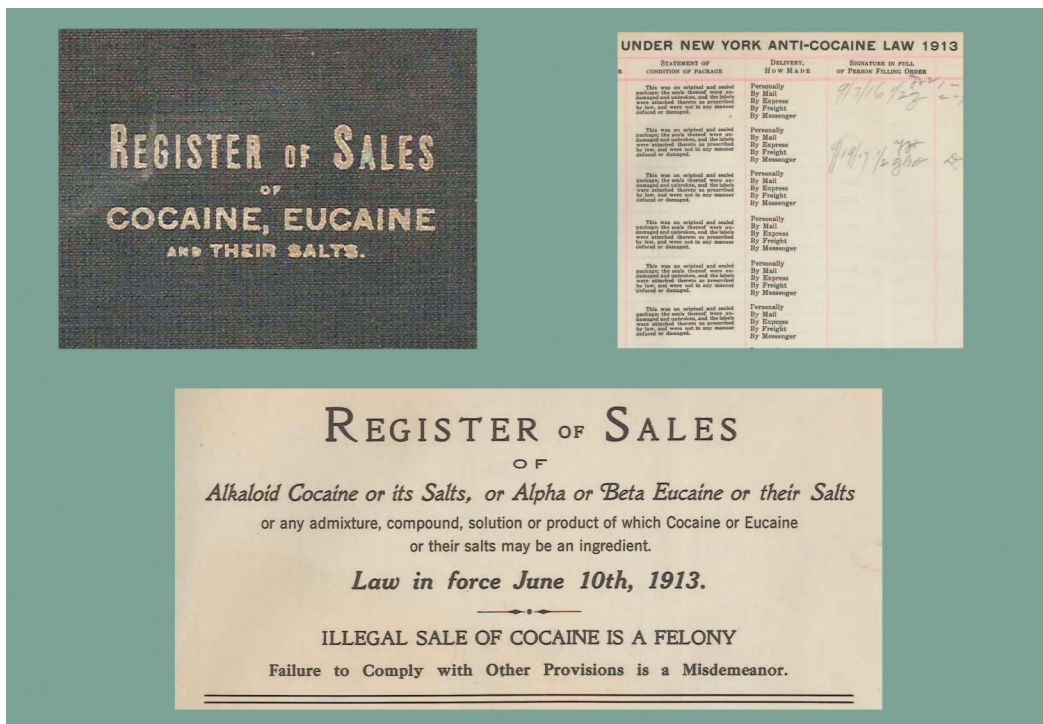
References

- Fedson S, Neithardt G, Thomas P, Lickerman A, Radzienda M, DeCara JM, Lang RM, Spencer KT: Unsuspected clinically important findings detected with a small portable ultrasound device in patients admitted to a general medicine service. *J Am Soc Echocardiogr* 2003; 16:901-5
- Bossone E, DiGiovine B, Watts S, Marcovitz PA, Carey L, Watts C, Armstrong WF: Range and prevalence of cardiac abnormalities in patients hospitalized in a medical ICU. *Chest* 2002; 122:1370-6
- Crone-Münzebrock W, Wegener C, Nicolas V, Pothmann W: The relevance of sonography in the diagnosis of acute abdomen in the intensive care unit. *Rofo* 1990; 153:379-84
- Schacherer D, Klebl F, Goetz D, Buettner R, Zierhut S, Schoelmerich J, Langgartner J: Abdominal ultrasound in the intensive care unit: A 3-year survey on 400 patients. *Intensive Care Med* 2007; 33:841-4
- Rozycki GS, Pennington SD, Feliciano DV: Surgeon-performed ultrasound in the critical care setting: Its use as an extension of the physical examination to detect pleural effusion. *J Trauma* 2001; 50:636-42
- Lichtenstein D, Axler O: Intensive use of general ultrasound in the intensive care unit. Prospective study of 150 consecutive patients. *Intensive Care Med* 1993; 19:353-5
- Le Gall JR, Lemeshow S, Saulnier F: A new Simplified Acute Physiology Score (SAPS II) based on a European/North American multicenter study. *JAMA* 1993; 270:2957-63
- Cohen J: A coefficient of agreement for nominal scales. *Educ Psychol Meas* 1960; 20:37-46
- Mayo PH, Beaulieu Y, Doelken P, Feller-Kopman D, Harrod C, Kaplan A, Oropello J, Vieillard-Baron A, Axler O, Lichtenstein D, Maury E, Slama M, Vignon P: American College of Chest Physicians/La Société de Réanimation de Langue Française statement on competence in critical care ultrasonography. *Chest* 2009; 135:1050-60
- Neri L, Storti E, Lichtenstein D: Toward an ultrasound curriculum for critical care medicine. *Crit Care Med* 2007; 35:S290-304
- Marik PE, Mayo P: Certification and training in critical care ultrasound. *Intensive Care Med* 2008; 34:215-7
- Mateer J, Plummer D, Heller M, Olson D, Jehle D, Overton D, Gussow L: Model curriculum for physician training in emergency ultrasonography. *Ann Emerg Med* 1994; 23:95-102
- Geeraerts T, Launey Y, Martin L, Pottecher J, Vigué B, Duranteau J, Benhamou D: Ultrasonography of the optic nerve sheath may be useful for detecting raised intracranial pressure after severe brain injury. *Intensive Care Med* 2007; 33:1704-11
- Kimberly HH, Shah S, Marill K, Noble V: Correlation of optic nerve sheath diameter with direct measurement of intracranial pressure. *Acad Emerg Med* 2008; 15:201-4
- Blaivas M, Theodoro D, Sierzenski PR: Elevated intracranial pressure detected by bedside emergency ultrasonography of the optic nerve sheath. *Acad Emerg Med* 2003; 10:376-81
- Mustafa S, Stein PD, Patel KC, Otten TR, Holmes R, Silbergleit A: Upper extremity deep venous thrombosis. *Chest* 2003; 123:1953-6
- Cronan JJ: Venous thromboembolic disease: The role of US. *Radiology* 1993; 186:619-30
- Monreal M, Lafoz E, Ruiz J, Valls R, Alastrue A: Upper-extremity deep venous thrombosis and pulmonary embolism. A prospective study. *Chest* 1991; 99:280-3
- Mathis G, Blank W, Reissig A, Lechleitner P, Reuss J, Schuler A, Beckh S: Thoracic ultrasound for diagnosing pulmonary embolism: A prospective multicenter study of 352 patients. *Chest* 2005; 128:1531-8
- Mansencal N, Vieillard-Baron A, Beauchet A, Farcot JC, El Hajjam M, Dufaitre G, Brun-Ney D, Lacombe P, Jardin F, Dubourg O: Triage patients with suspected pulmonary embolism in the emergency department using a portable ultrasound device. *Echocardiography* 2008; 25:451-6
- McLoud TC, Flower CD: Imaging the pleura: Sonography, CT, and MR imaging. *AJR Am J Roentgenol* 1991; 156:1145-53
- Lichtenstein D, Goldstein I, Mourgeon E, Cluzel P, Grenier P, Rouby JJ: Comparative diagnostic performances of auscultation, chest radiography, and lung ultrasonography in acute respiratory distress syndrome. *ANESTHESIOLOGY* 2004; 100:9-15
- Fartoukh M, Azoulay E, Galliot R, Le Gall JR, Baud F, Chevret S, Schlemmer B: Clinically documented pleural effusions in medical ICU patients: How useful is routine thoracentesis? *Chest* 2002; 121:178-84
- Mattison LE, Coppage L, Alderman DF, Herlong JO, Sahn SA: Pleural effusions in the medical ICU: Prevalence, causes, and clinical implications. *Chest* 1997; 111:1018-23
- Balik M, Plasil P, Waldauf P, Pazout J, Fric M, Otahal M, Pachel J: Ultrasound estimation of volume of pleural fluid in mechanically ventilated patients. *Intensive Care Med* 2006; 32:318-2
- Remérand F, Dellamonica J, Mao Z, Ferrari F, Bouhemad B, Jianxin Y, Arbelot C, Lu Q, Ichai C, Rouby JJ: Multiplane ultrasound approach to quantify pleural effusion at the bedside. *Intensive Care Med* 2010; 36:656-4
- Doelken P, Abreu R, Sahn SA, Mayo PH: Effect of thoracentesis on respiratory mechanics and gas exchange in the patient receiving mechanical ventilation. *Chest* 2006; 130:1354-61
- Kopterides P, Lignos M, Papanikolaou S, Papadomichelakis E, Mentzelopoulos S, Armaganidis A, Panou F: Pleural effusion causing cardiac tamponade: Report of two cases and review of literature. *Heart Lung* 2006; 35:66-7
- Blaivas M, Lyon M, Duggal S: A prospective comparison of supine chest radiography and bedside ultrasound for the diagnosis of traumatic pneumothorax. *Acad Emerg Med* 2005; 12:844-9
- Zhang M, Liu ZH, Yang JX, Gan JX, Xu SW, You XD, Jiang GY: Rapid detection of pneumothorax by ultrasonography in patients with multiple trauma. *Crit Care* 2006; 10:R112
- Lichtenstein DA, Mezière G, Lascols N, Biderman P, Courret JP, Gepner A, Goldstein I, Tenoudji-Cohen M: Ultrasound diagnosis of occult pneumothorax. *Crit Care Med* 2005; 33:1231-8
- Woodring JH: Recognition of pleural effusion on supine radiographs: How much fluid is required? *AJR Am J Roentgenol* 1984; 142:59-64
- Lichtenstein DA, Mezière G: Relevance of lung ultrasound in the diagnosis of acute respiratory failure: The BLUE protocol. *Chest* 2008; 134:117-25
- Volpicelli G, Cardinale L, Garofalo G, Veltri A: Usefulness of lung ultrasound in the bedside distinction between pulmonary edema and exacerbation of COPD. *Emerg Radiol* 2008; 15:145-51
- Reissig A, Copetti R, Kroegel C: Current role of emergency ultrasound of the chest. *Crit Care Med* 2011; 39:839-45
- Manasia AR, Nagaraj HM, Kodali RB, Croft LB, Oropello JM, Kohli-Seth R, Leibowitz AB, DelGiudice R, Hufanda JF, Benjamin E, Goldman ME: Feasibility and potential clinical utility of goal-directed transthoracic echocardiography performed by noncardiologist intensivists using a small hand-carried

- device (SonoHeart) in critically ill patients. *J Cardiothorac Vasc Anesth* 2005; 19:155-9
37. Molenat F, Boussuges A, Valantin V, Sainty JM: Gallbladder abnormalities in medical ICU patients: An ultrasonographic study. *Intensive Care Med* 1996; 22:356-8
 38. Liteplo AS, Murray AF, Kimberly HH, Noble VE: Real-time resolution of sonographic B-lines in a patient with pulmonary edema on continuous positive airway pressure. *Am J Emerg Med* 2010; 28:541.e5-8
 39. Via G, Lichtenstein D, Mojoli F, Rodi G, Neri L, Storti E, Klersy C, Iotti G, Braschi A: Whole lung lavage: A unique model for ultrasound assessment of lung aeration changes. *Intensive Care Med* 2010; 36:999-1007
 40. Bouhemad B, Brisson H, Le-Guen M, Arbelot C, Lu Q, Rouby JJ: Bedside ultrasound assessment of positive end-expiratory pressure-induced lung recruitment. *Am J Respir Crit Care Med* 2011; 183:341-7
 41. Eisen LA, Leung S, Gallagher AE, Kvetan V: Barriers to ultrasound training in critical care medicine fellowships: A survey of program directors. *Crit Care Med* 2010; 38:1978-83

ANESTHESIOLOGY REFLECTIONS FROM THE WOOD LIBRARY-MUSEUM

Cocaine/Eucaine Sales Register: *Déjà Vu* or *Tête-bêche*?



If this image of a *Cocaine and Eucaine Register of Sales* seems like *déjà vu*, that is because it is the “reverse” or “upside-down” book built into the opposite pagings of the *Cocaine and Eucaine Register of Purchases*, which was featured as one of our September 2012 Anesthesiology Reflections. Such an unusual binding is called a *tête-bêche* (French for “head-to-toe”). In other words, if you start at the front cover of the *Purchases*, read right-hand pages to the last page, close the book to reveal the back cover, and then rotate the book 180 degrees, you will see that *Purchase’s* back cover is actually the upside-down front cover of *Sales*. Now if you were a librarian at the Wood Library-Museum, how would you shelve *Sales*— upside up or upside down? (Copyright © the American Society of Anesthesiologists, Inc.)
 George S. Bause, M.D., M.P.H., Honorary Curator, ASA’s Wood Library-Museum of Anesthesiology, Park Ridge, Illinois, and Clinical Associate Professor, Case Western Reserve University, Cleveland, Ohio. UJYC@aol.com.