

TIPSHEET: .USTTE (CPT 93308)

Indication: suspicion of pericardial effusion or to evaluate cardiac activity

Questions you should ask yourself:

- Pericardial fluid: YES or NO
- Right ventricle size: ENLARGED or unable to determine
- LV Contractility: POOR or NORMAL or HYPERDYNAMIC
- RV Contractility: POOR or NORMAL or HYPERDYNAMIC
- IVC size: SIZE in CM or NOT visualized
- Mechanically ventilated breaths: YES or NO
- Diuretics given in past 12 hours (example furosemide): YES or NO
- Vasodilators given in past 12 hours: YES or NO
- IF any of above YES do not perform IVC respiratory variation test
- IVC respiratory variation %: NO variation or 30-50% or Greater than 50% or UNABLE to perform

Intravascular volume status: Volume depletion OR normal OR volume overload

Images to obtain:

Probe: Low Frequency Phased Array

- TTE1 – Parasternal Long View
- TTE2 – Parasternal Short View (M-mode through center of LV) and record clip
- TTE3 – Apical View (Optional) to compare RV to LV size
- TTE4 – IVC (M-mode image) to show respiratory variation % and record clip
- TTE5 – BLUE point (upper right)
- TTE5.1 – BLUE point (upper left)

Scanning Tips:

Parasternal long view:

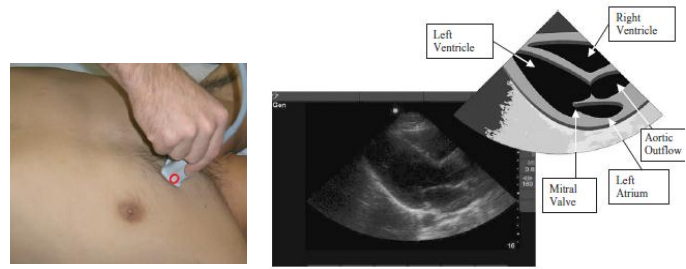
- Ribs in way?* Try turning probe slightly clockwise or counterclockwise
- Can't see recognizable image?* Try sliding probe along third or fourth intercostal space toward and away from sternum, heart sometimes in middle of thorax

Parasternal short view:

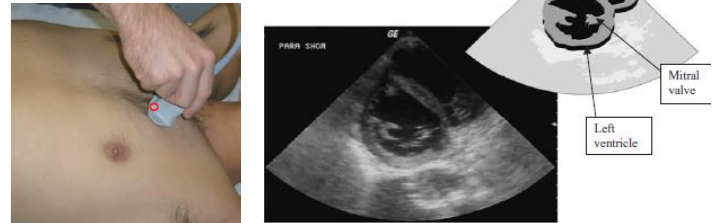- Can't see recognizable image?* As above on parasternal long view; sometimes placing person in left lateral decubitus position will help

Apical view:

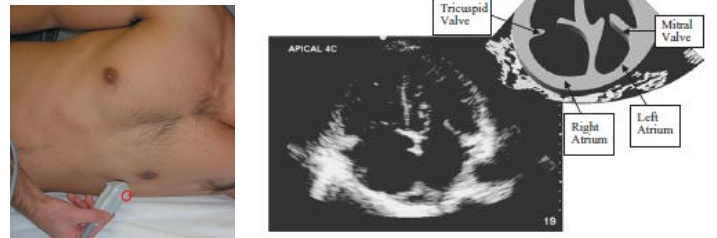
- Same as above, hardest view to find sometimes. Attempt to place person in left lateral decubitus position



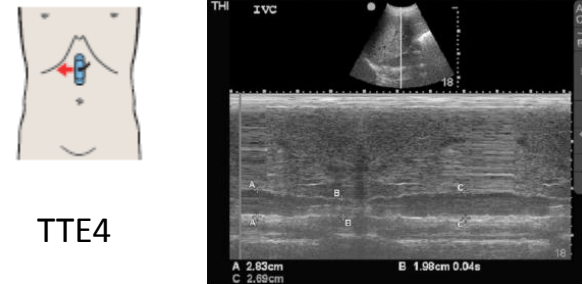TTE1



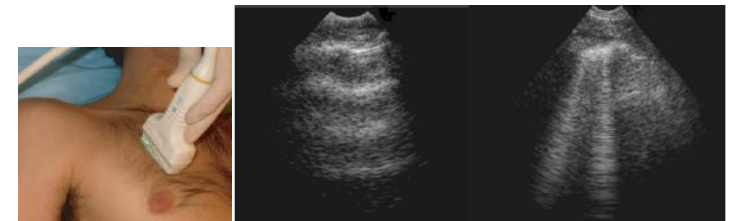
TTE2



TTE3



TTE4



TTE5

A lines

B lines

IVC unable to be located? Air in stomach or abdomen can obscure view, try obtaining view through hepatic window

Lung views for pneumothorax and hemothorax:

- Can't see pleural line?* If unable to locate anything might have subcutaneous air, try different lung positions.
- Can't see above diaphragm?* Try positioning more posterior and slide probe up towards head