

Lung ultrasound in the critically ill patient Pleural Effusions



Rohit Patel, MD
University of Florida Health
Director, Critical Care Ultrasound Surgical ICU
Center for Intensive Care
Gainesville, Florida

Critical Care Ultrasound

A lines Bat sign B lines

B3 lines B7 lines BLUE protocol

BLUE points Comet tails Sinusoid sign

Jellyfish sign Lung point Merlin's space

PLAPS Point Quad sign Seashore sign

Shred sign Stratosphere sign

Tissue like sign Z lines

What can I find?

Pneumothorax

Hemothorax

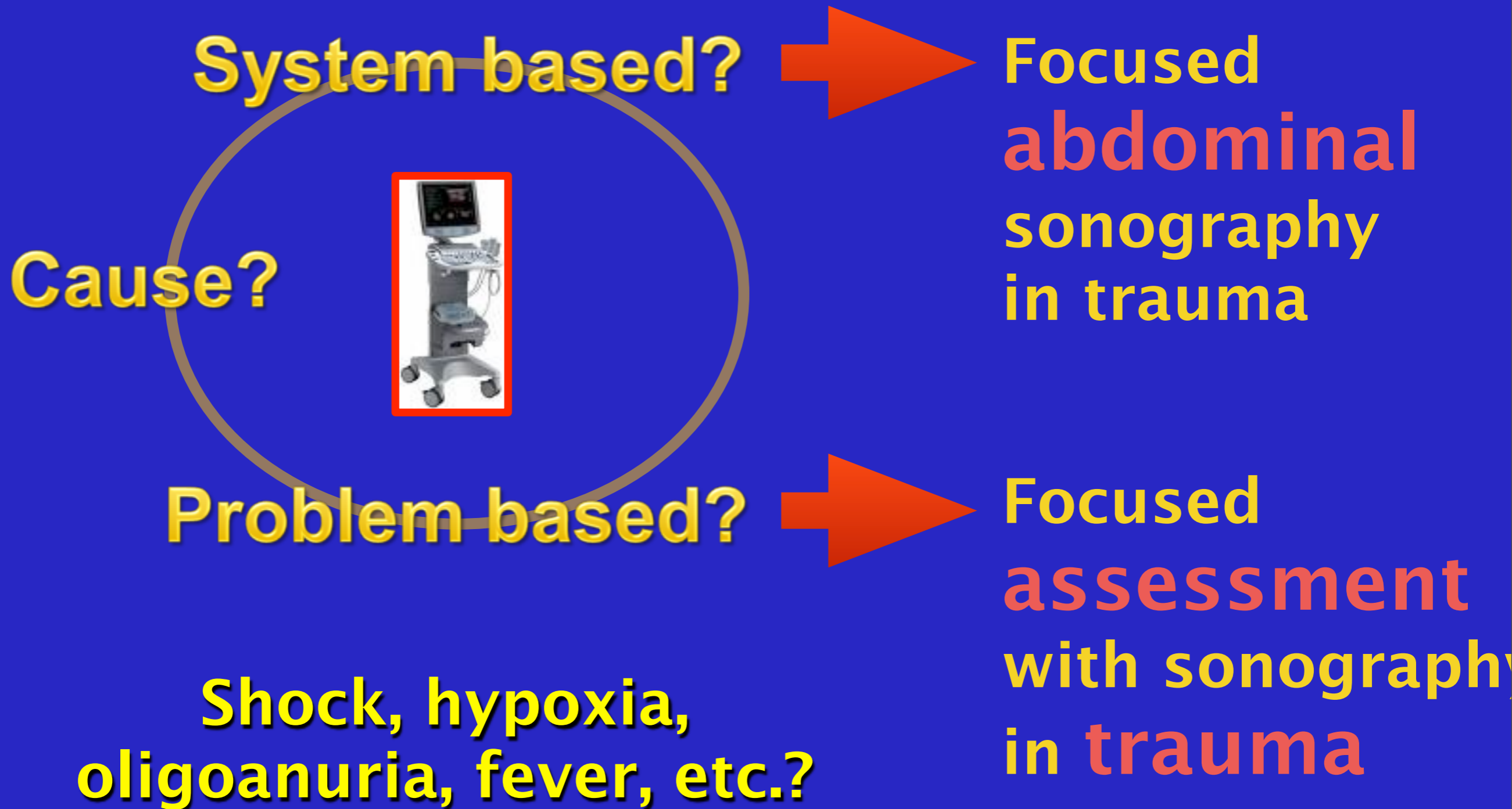
Other pleural effusions

Alveolar consolidation

Pulmonary edema and/or extravascular lung water

Pulmonary embolism?

What are the questions?



Principles of lung ultrasound

Nearly all acute disorders of the thorax come in contact with the surface

Pleural effusions and pneumothorax always reaches pleural line

Alveolar consolidations touch chest wall in nearly all acute conditions

Acute interstitial changes involve deep areas as well as superficial


Pleural effusions

Focused Questions:

How much fluid is present?

Where is best location to do procedure?

Probe: Abdominal probe



Pleural effusion – introduction

Common in critically ill patients – 62% in MICU, 41% present on admission

This application in itself might be reason enough to use US

Evaluates volume, nature of effusion, and best location

Collects in dependent areas

Traditionally located from abdominal exam, but to be more consistent should be done through PLAPS point – "one shot" should be this location

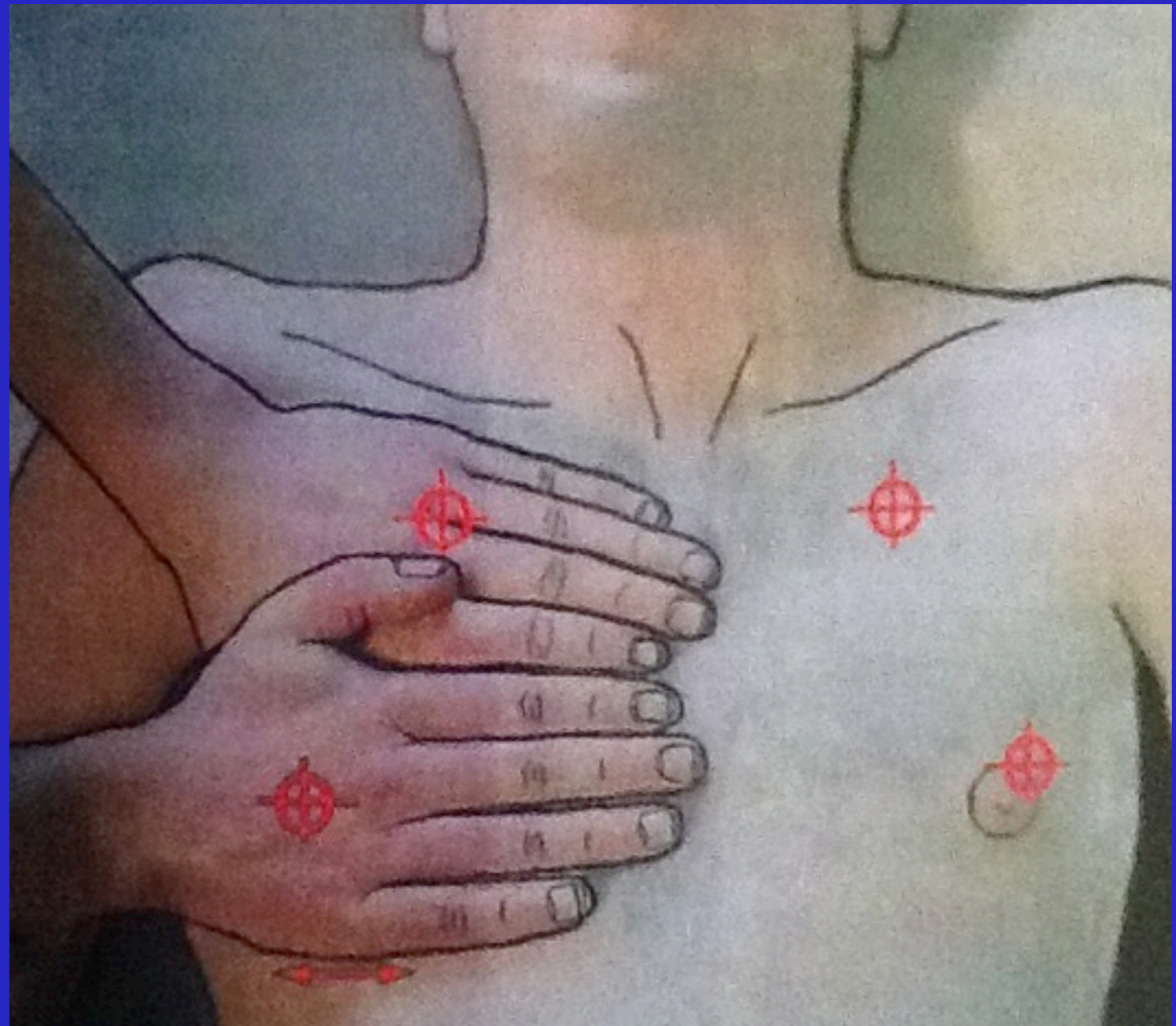
Mattison. Chest.
1997

Principles of lung ultrasound

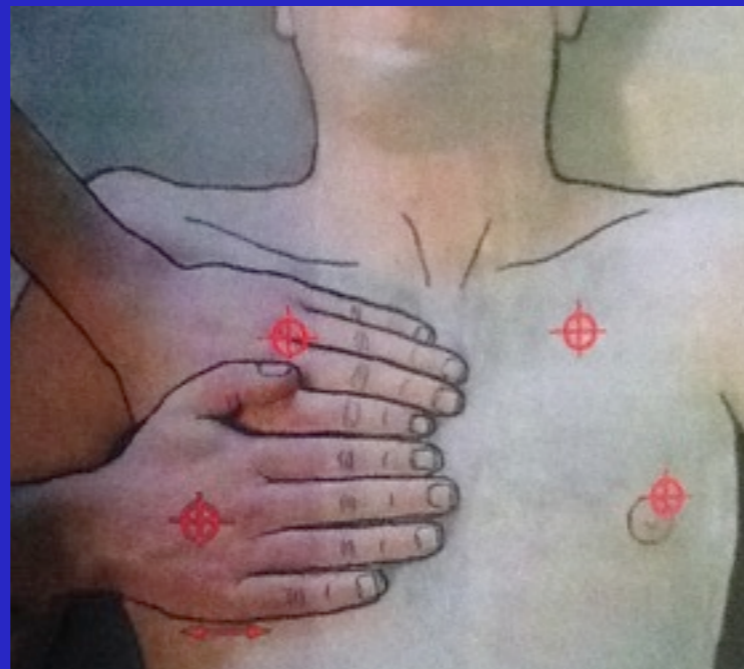Anterior zone = "BLUE hands"

Lateral zone

Posterior zone



Lichtenstein. Textbook. Whole body ultrasonography in the critically ill.



Upper BLUE point: between third and fourth finger of BLUE hand, at palmar insertion

Lower BLUE point: middle of palm of lower BLUE hand; allows for avoidance of heart in most cases

Phrenic line: continuation of this line locates the lateral place

PLAPS point: "posterior and/or lateral alveolar and/or pleural syndrome" -- intersection between the posterior axillary line and the transversal line continuing posteriorly to the lower BLUE point; also can have extended PLAPS points

Principles of lung ultrasound

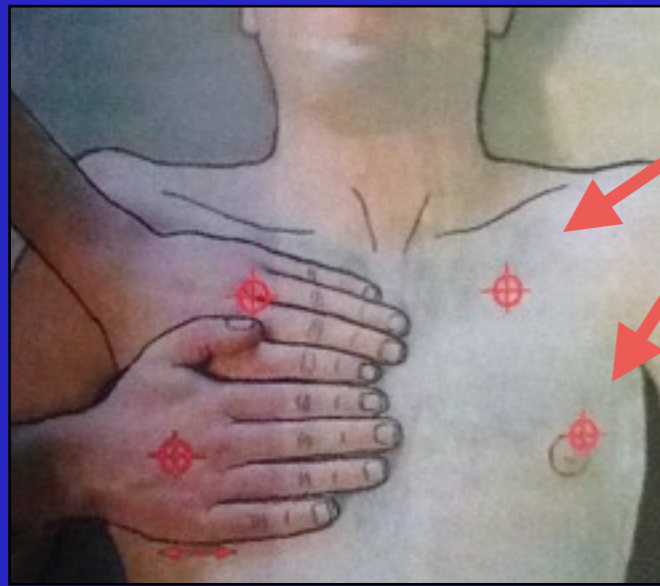
Stage 1: anterior wall

Stage 2: adds lateral wall from anterior to posterior axillary line

Stage 3: external part of the posterior wall; aim from back towards sky; no visual control of probe so need to hold with whole hand; can depress bed if need to

Stage 4: patients must be positioned laterally or sitting; can also study the apex

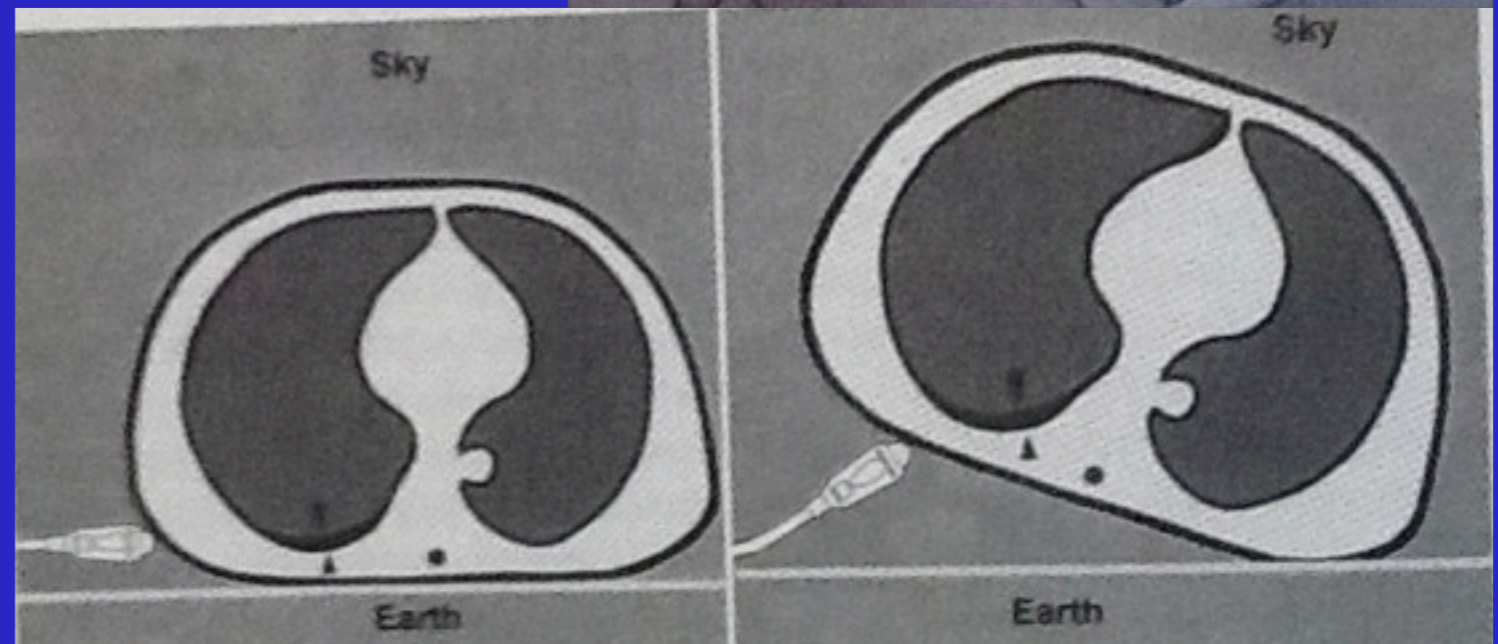
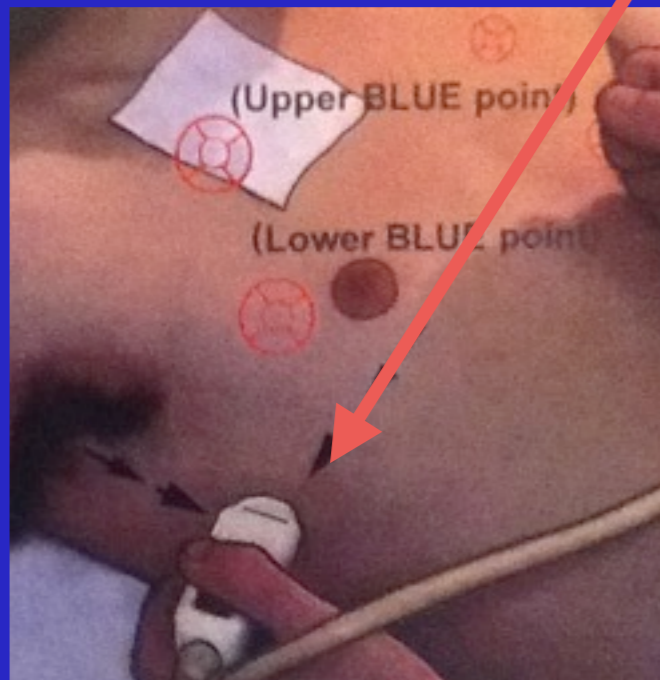
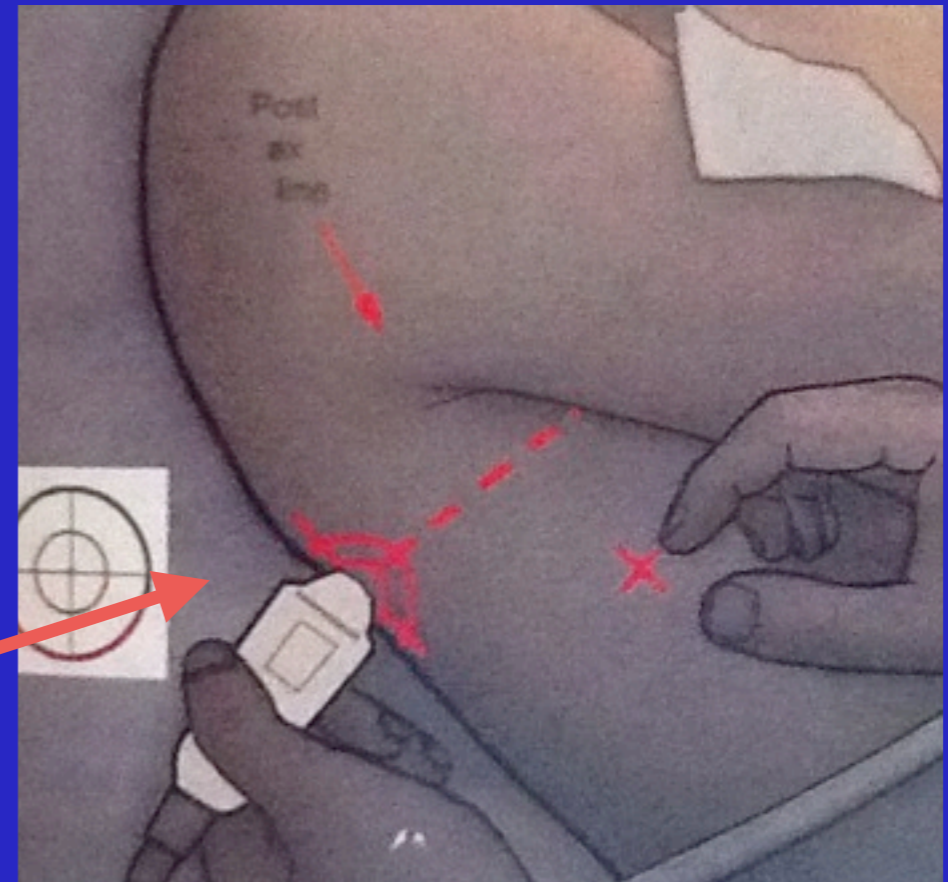
Principles of lung ultrasound



Upper and Lower BLUE points

Phrenic point

PLAPS point



Lichtenstein. Textbook. Whole body ultrasonography in the critically ill.

Pleural effusion – the signs

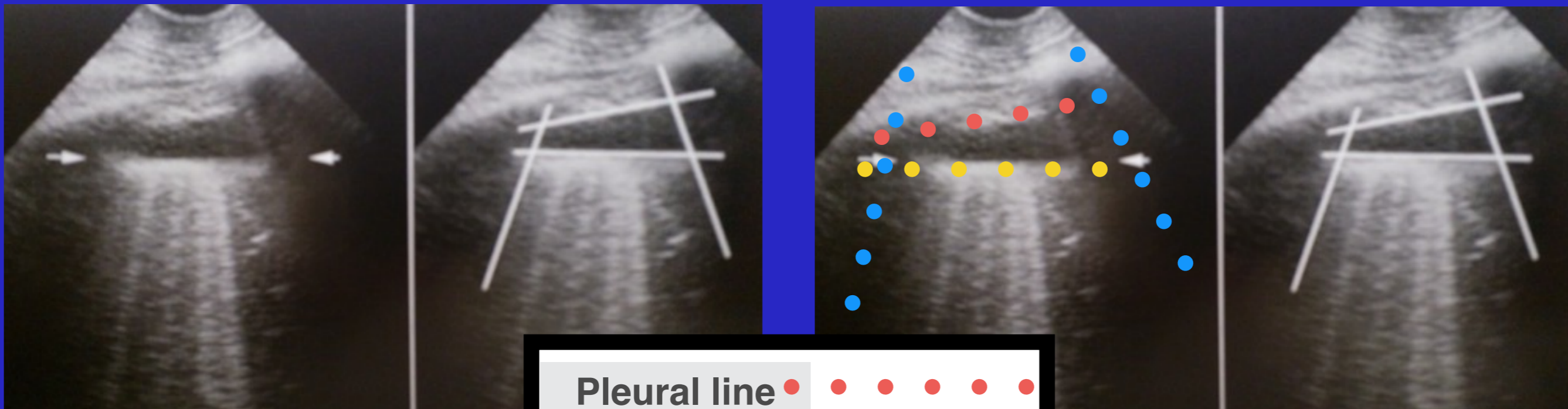
Quad sign: static sign, borders are pleural line, upper and lower shadows of rib, and the deep border which is always roughly parallel to the pleural line and regular (represents lung surface)

Jellyfish sign: aerated lung floats over effusion; as lung becomes more injured it becomes more towards same density as fluid surrounding it (looks like algae...)

Sinusoid sign: dynamic sign, respiratory variation of the interpleural distance

Pleural effusion – Quad sign

More on deep border: This line is called the lung line and is the visceral pleura; and visible when both pleura are separated by a structure that allows ultrasound transmission; the lung itself can be normal, show alveolar consolidation, or B lines



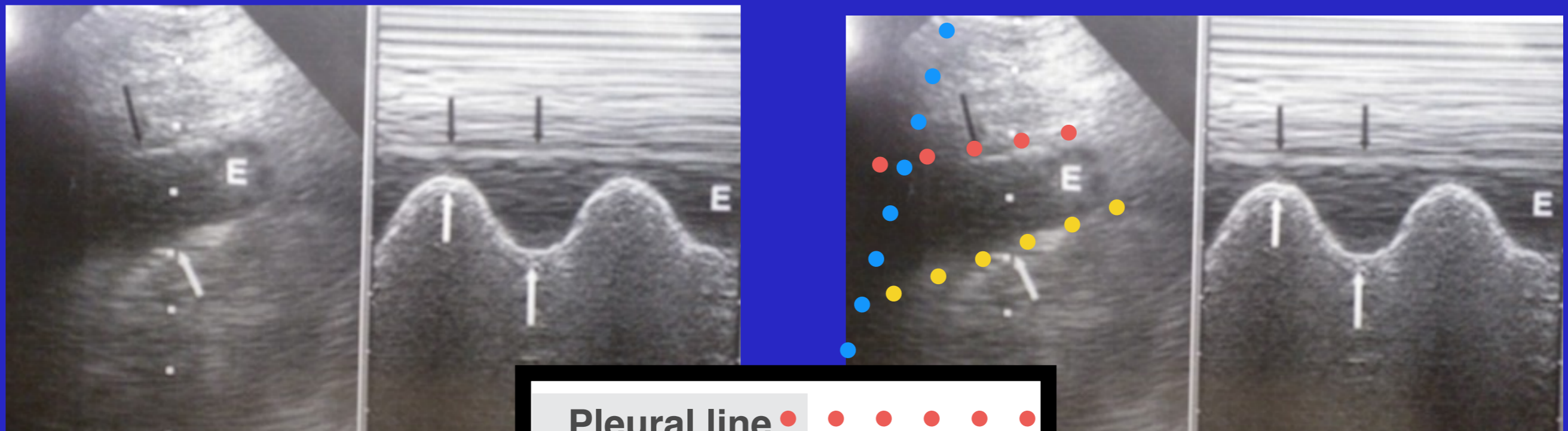
Pleural line	●	●	●	●	●
Rib shadows	●	●	●	●	●
Lung line	●	●	●	●	●

Lichtenstein. Textbook.
Whole body ultrasonography
in the critically ill.

Pleural effusion – sinusoid sign

Sinusoid sign: dynamic sign, respiratory variation of the interpleural distance

Also indicates low viscosity; very viscous or septate will not show Sinusoid sign



Pleural line ● ● ● ● ● ●
Rib shadows ● ● ● ● ● ●
Lung line ● ● ● ● ● ●

Lichtenstein. Textbook.
Whole body ultrasonography
in the critically ill.

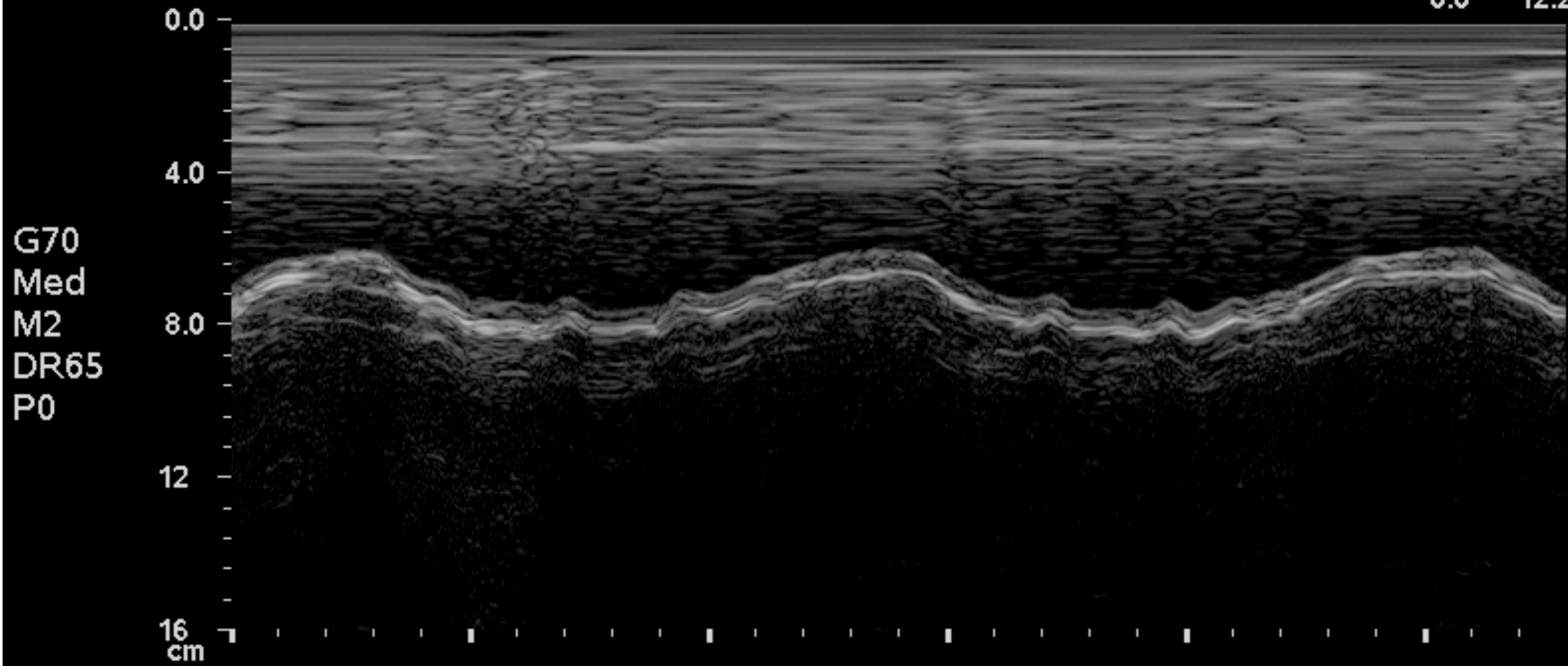
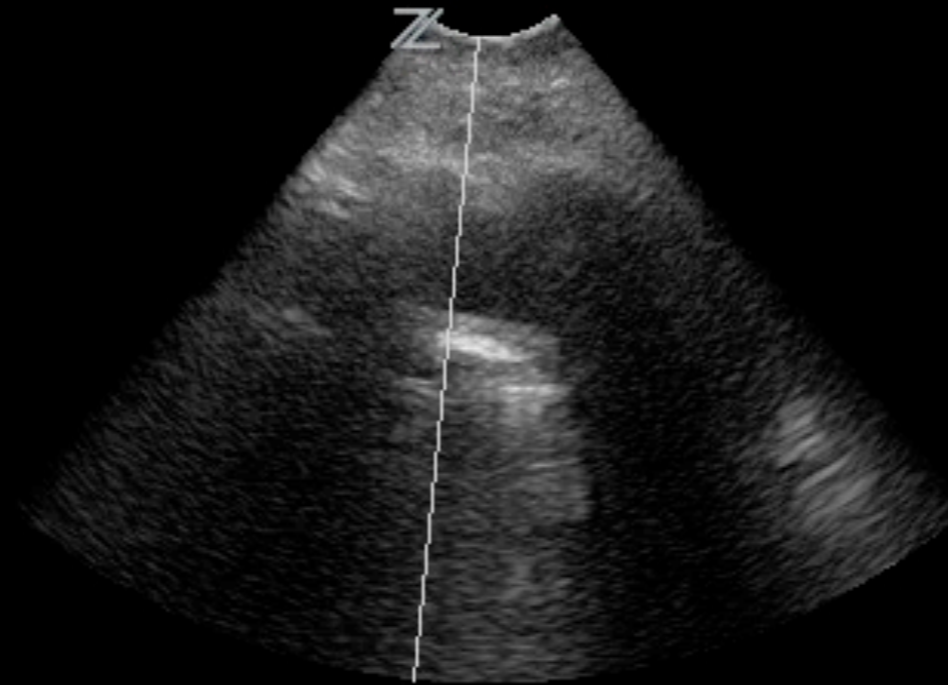DELEDDA/DALALY, WH
ID_20120803_111110

SHANDS SOUTH TOWER

08/03/12
11:19:33 AM

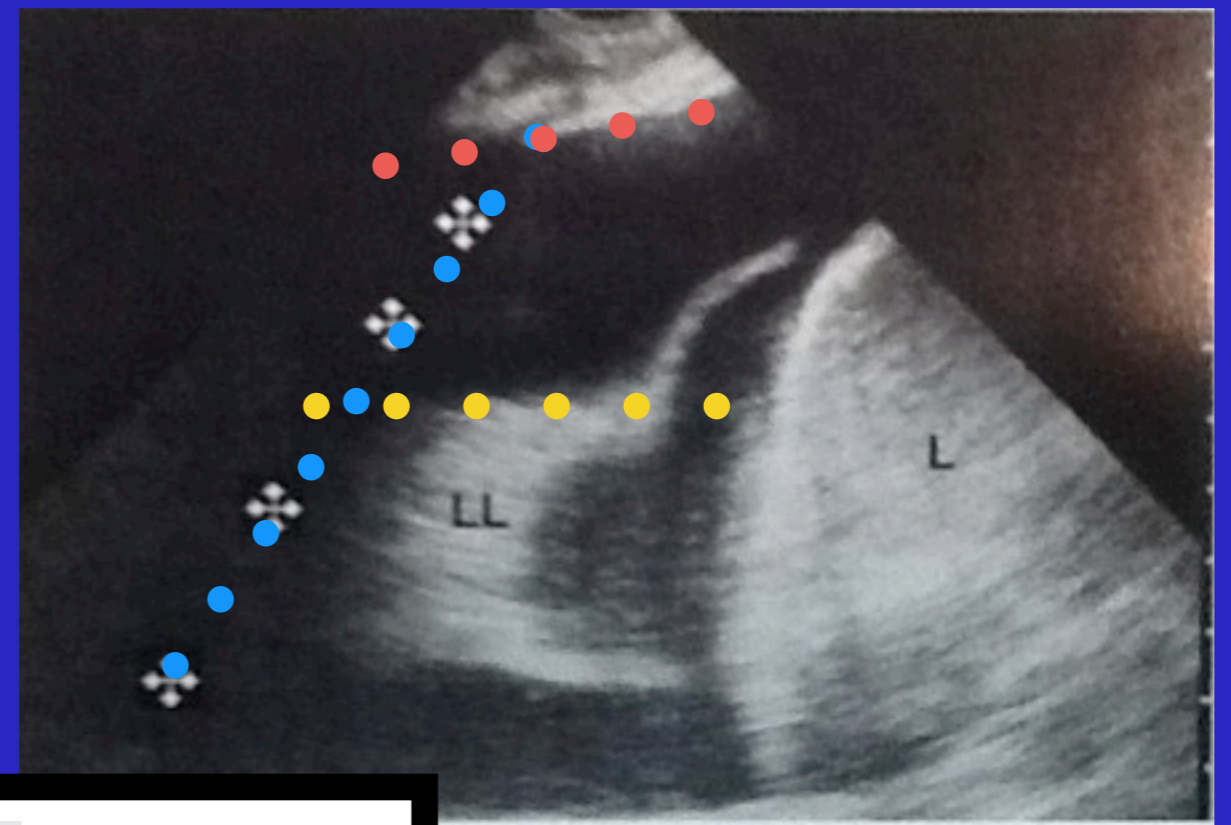
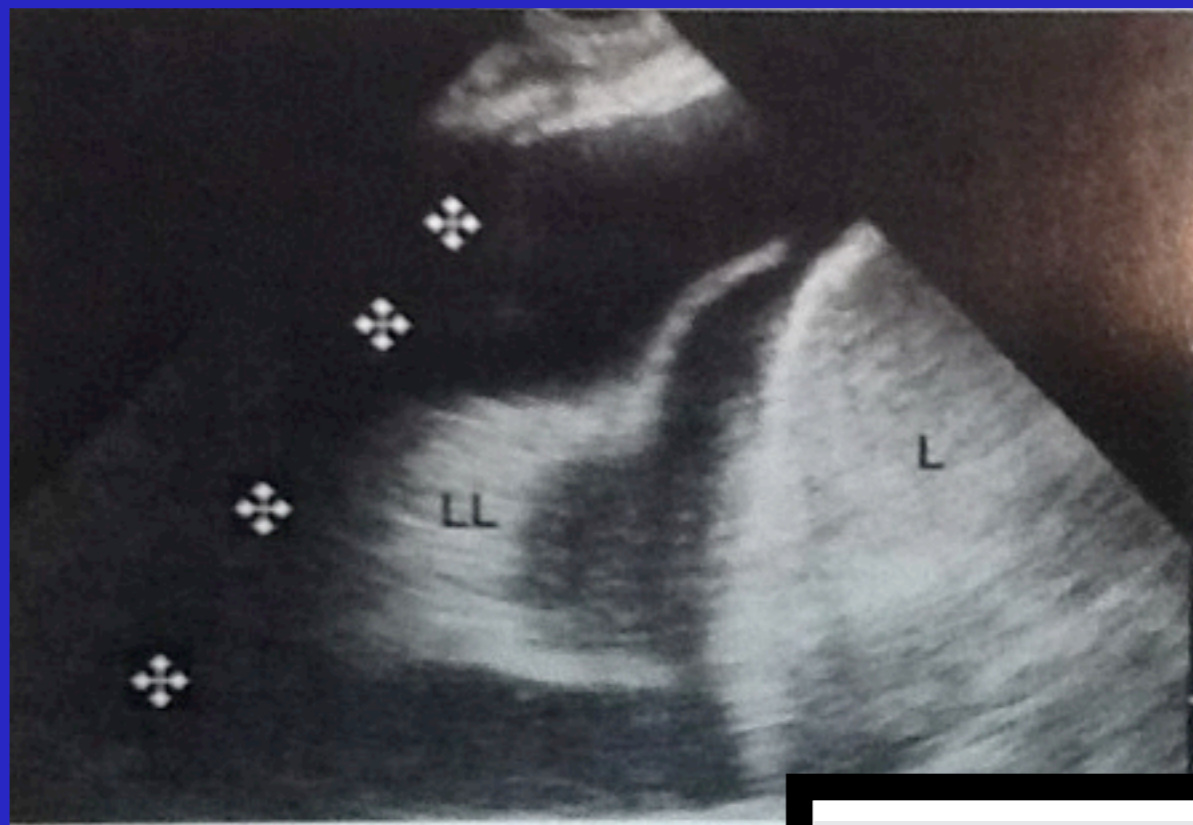
— Abd/General
— C4-1/H3.5MHz
— DR60/M3/P2
— G80/E1/100%
— MI1.4 TIs0.4
— 16.0 cm
— 10 Hz
— Δ ZSI 10
— Cine
— 0.0 12.2

LEFT



Pleural effusion – jellyfish sign

Jellyfish sign: aerated lung floats over effusion; as lung becomes more injured it becomes more towards same density as fluid surrounding it (looks like algae...)

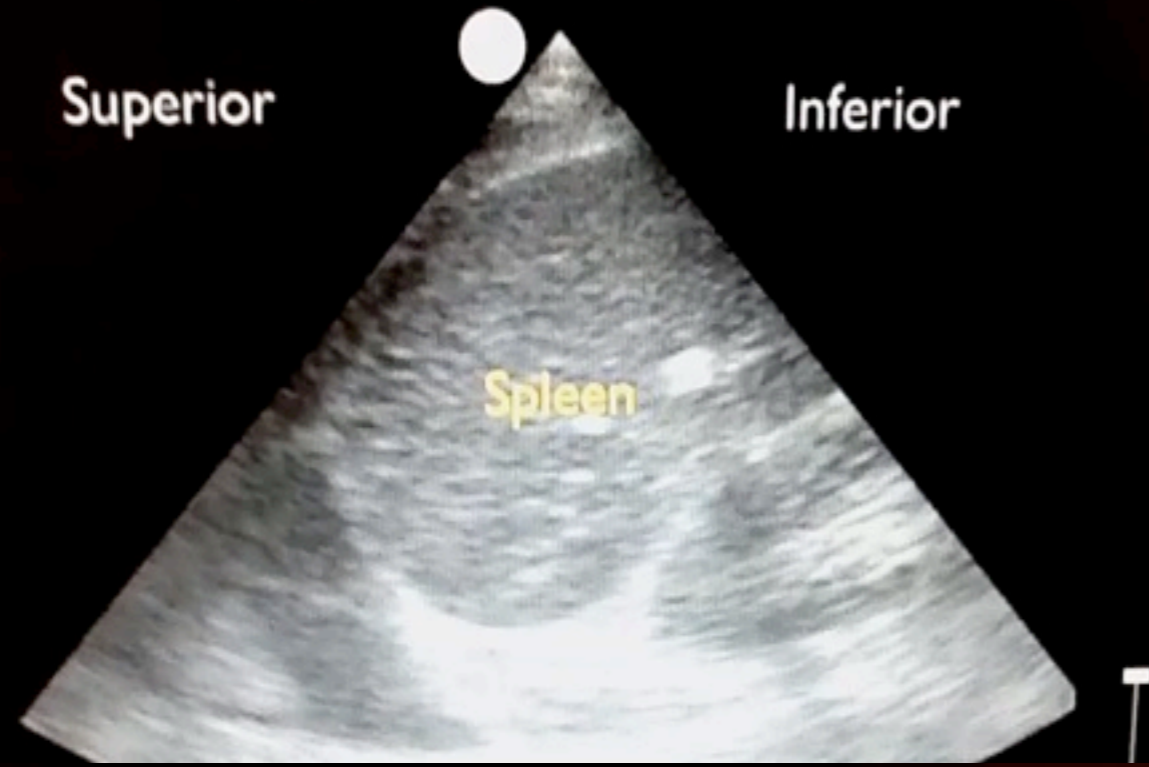


Pleural line	●	●	●	●	●
Rib shadows	●	●	●	●	●
Lung line	●	●	●	●	●

Lichtenstein. Textbook.
Whole body ultrasonography
in the critically ill.

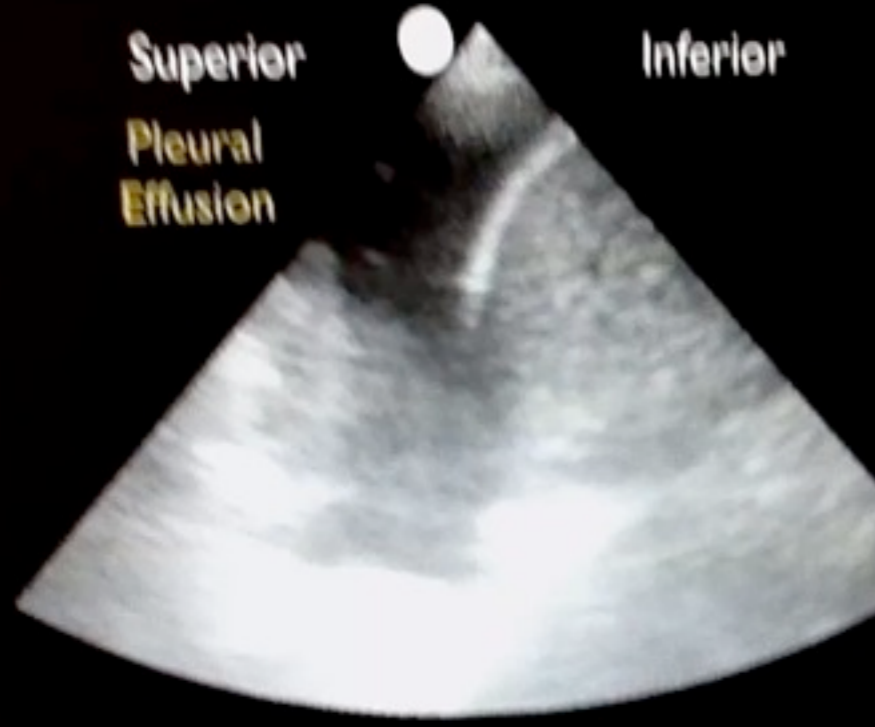Video

Small Pleural Effusion

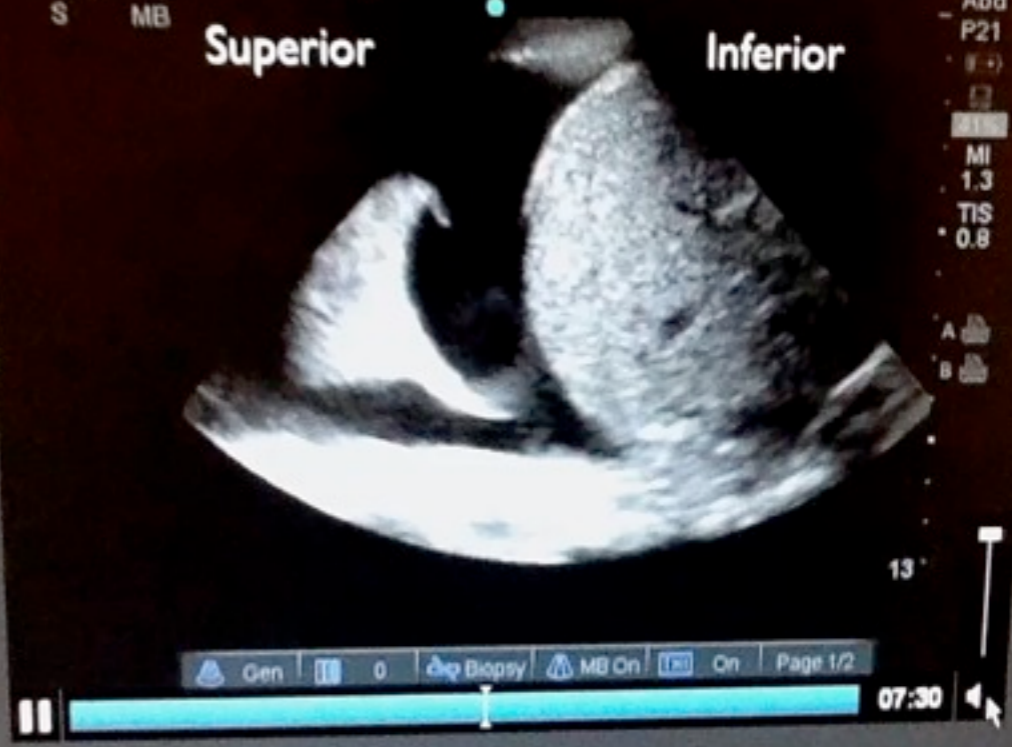

Perera P. "<http://www.sound-bytes.tv>"

Moderate Pleural Effusion



Large Pleural Effusion

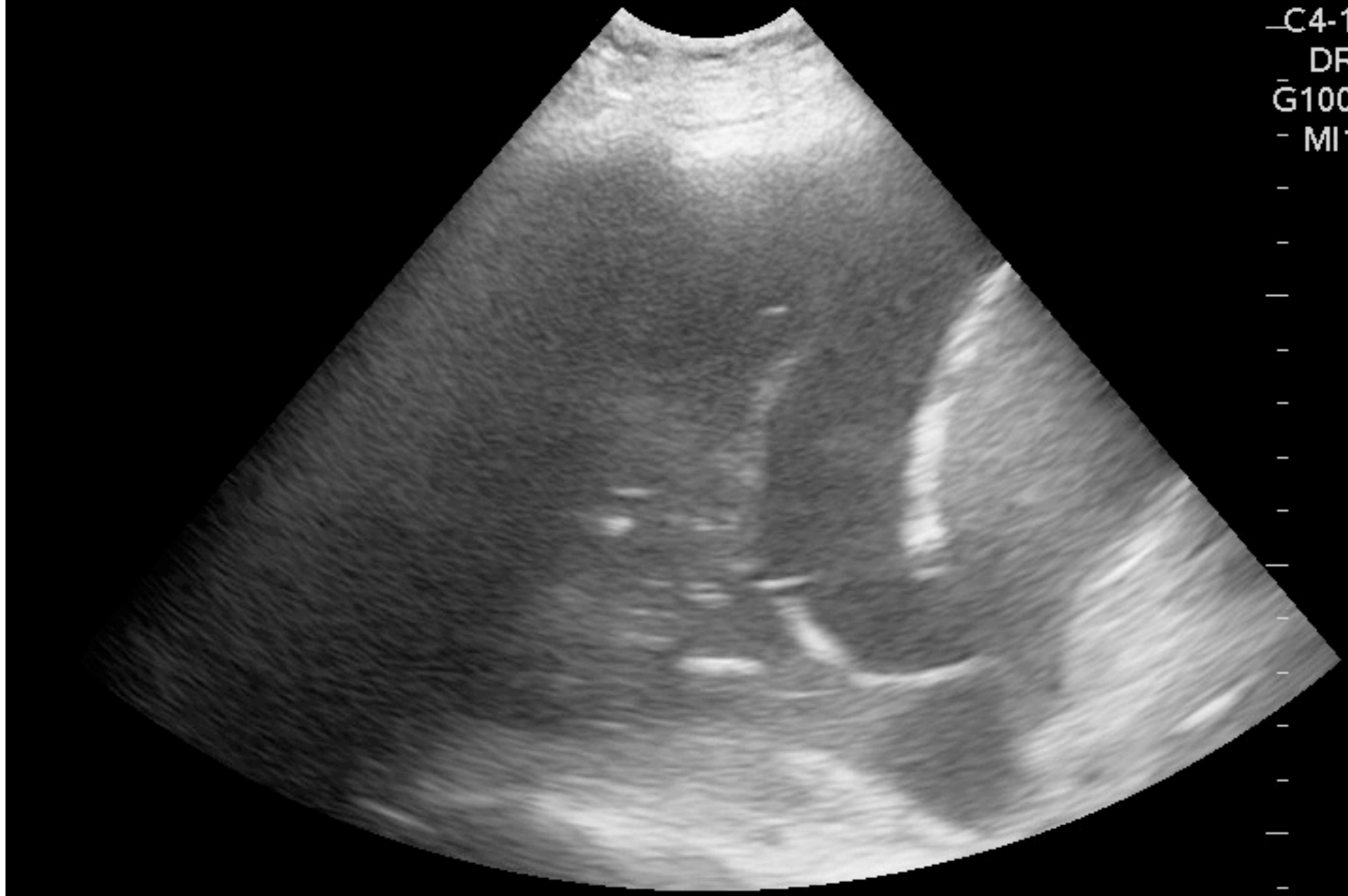


SHANDS SOUTH TOWER

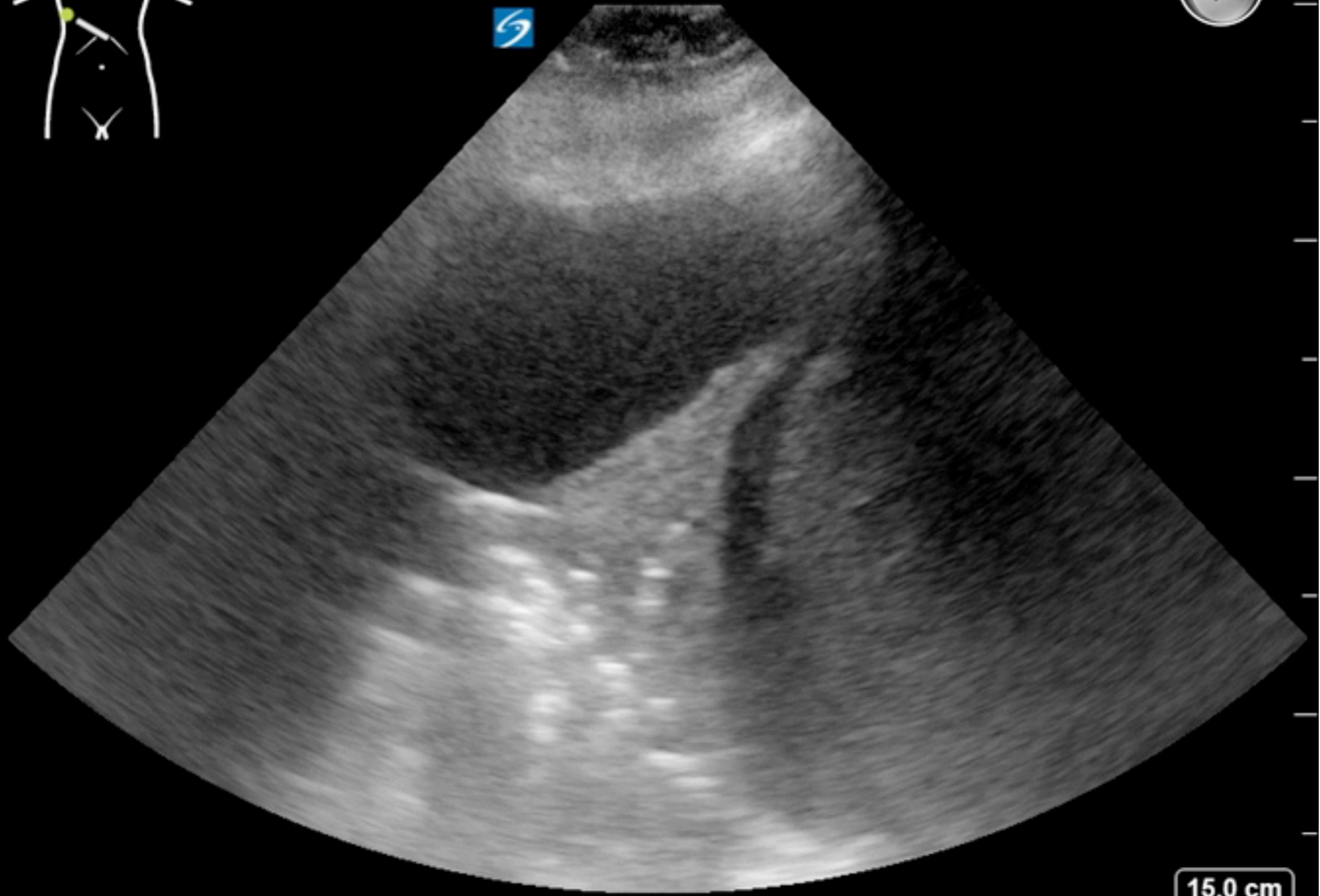
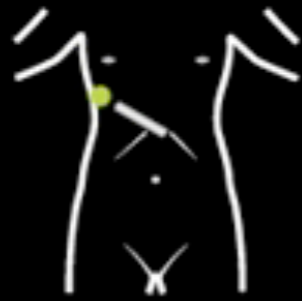12/09/13
MROSENTHAL 2:59:25 PM

Z

Abd/General
_C4-1/CH4MHz
DR60/M3/P2
G100/E1/100%
- MI1.3 TIs0.4
- 16.0 cm
- 11 Hz
- ZSI 0
Image



10 Sep 2015 / 13:19



VANAM
TRAUMA
EUF

SonoSite
P21xp/5-1 Abdomen
MI: 1.1 TIS: 0.6

15.0 cm

2D: G: 50
DR: 0



THI

Pleural effusion – are we done?

Transudate, exudate, purulent pleurisy

MICU: cardiac failure (35%), atelectasis (23%),
parapneumonic (11%), empyema (1%)

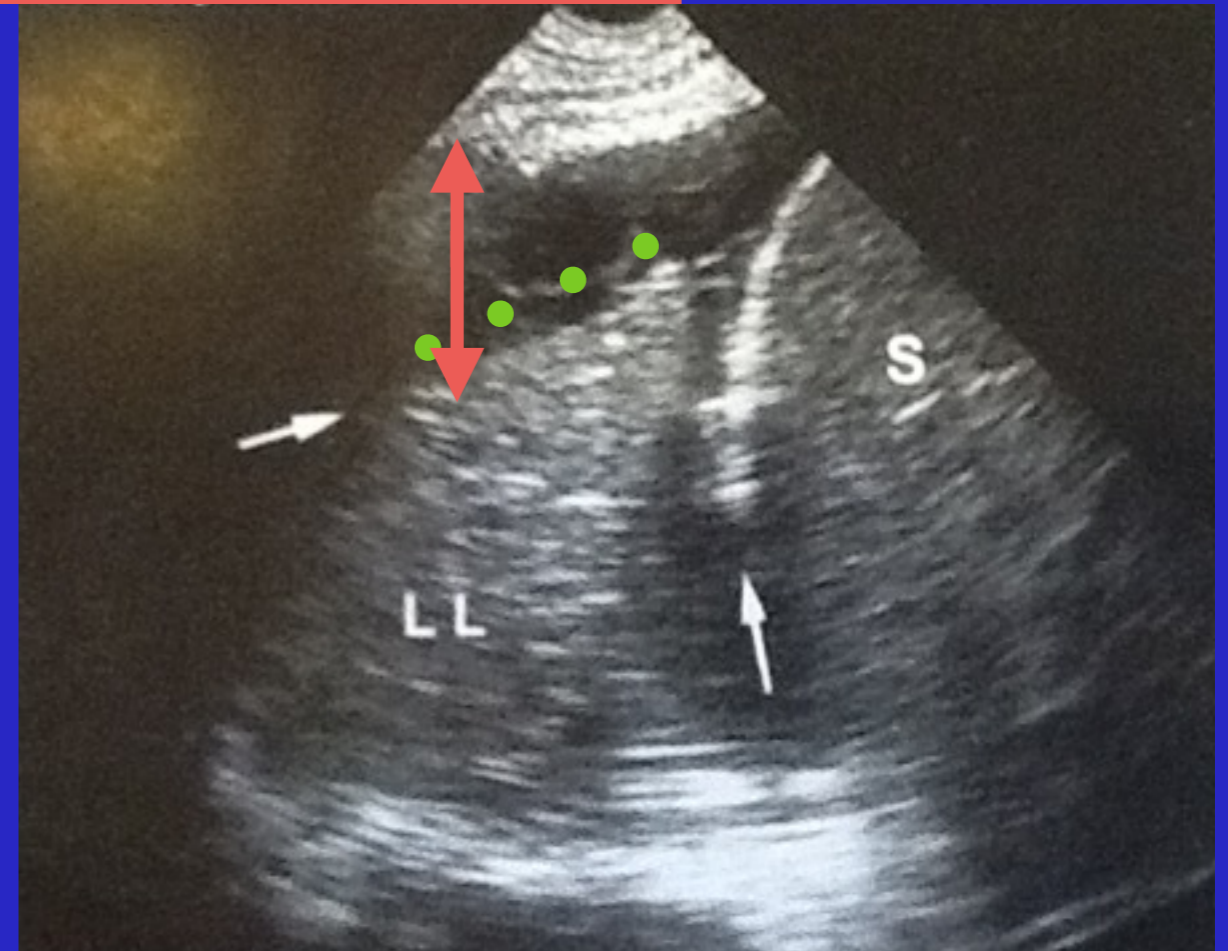
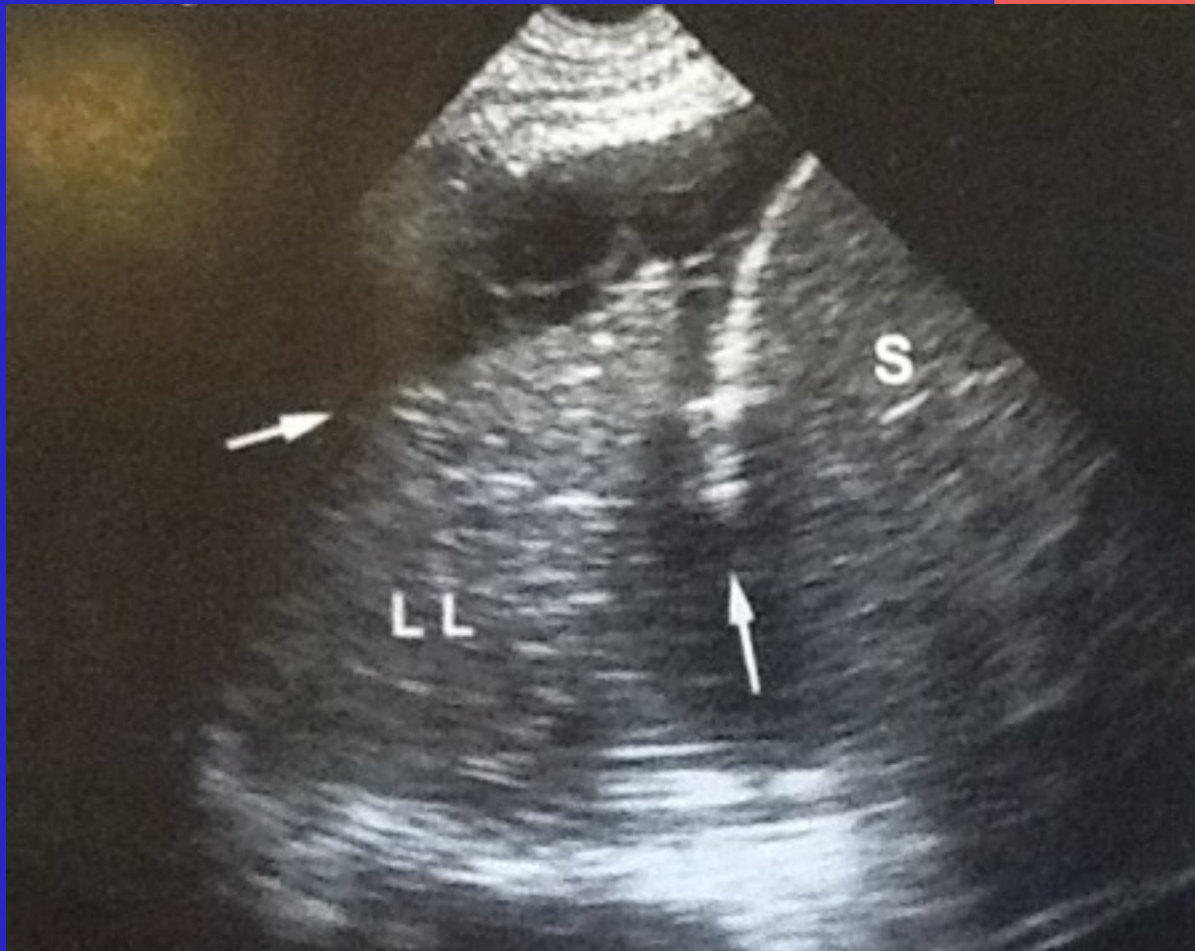Transudates are anechoic, anechoic effusions can be transudates or exudates, and all echoic effusions are exudates

Ultrasound not reliable for indicating puncture is not necessary

Mattison. Chest. 1997
Yang. AJR AM J Rad.
1997

Pleural effusion – are we done?

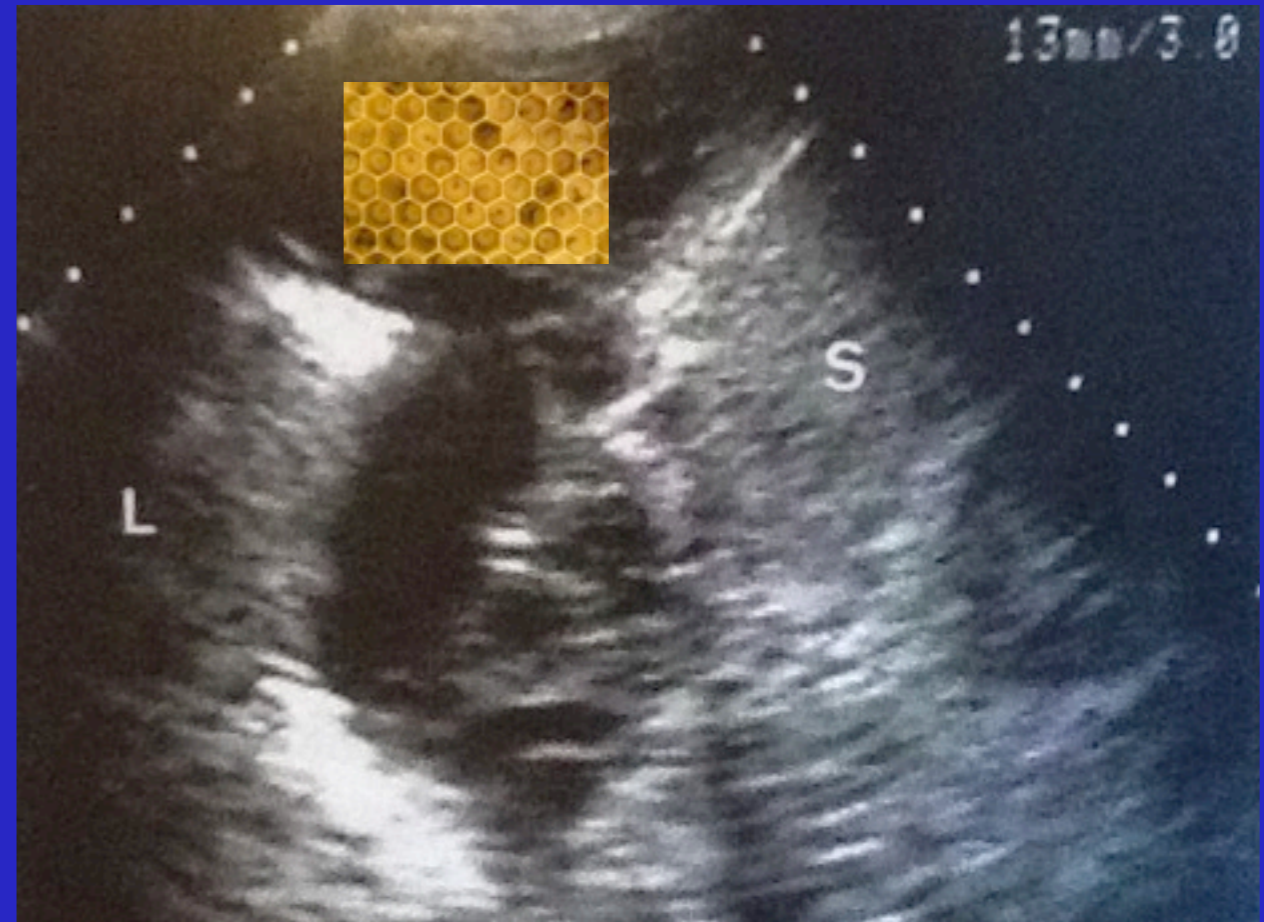
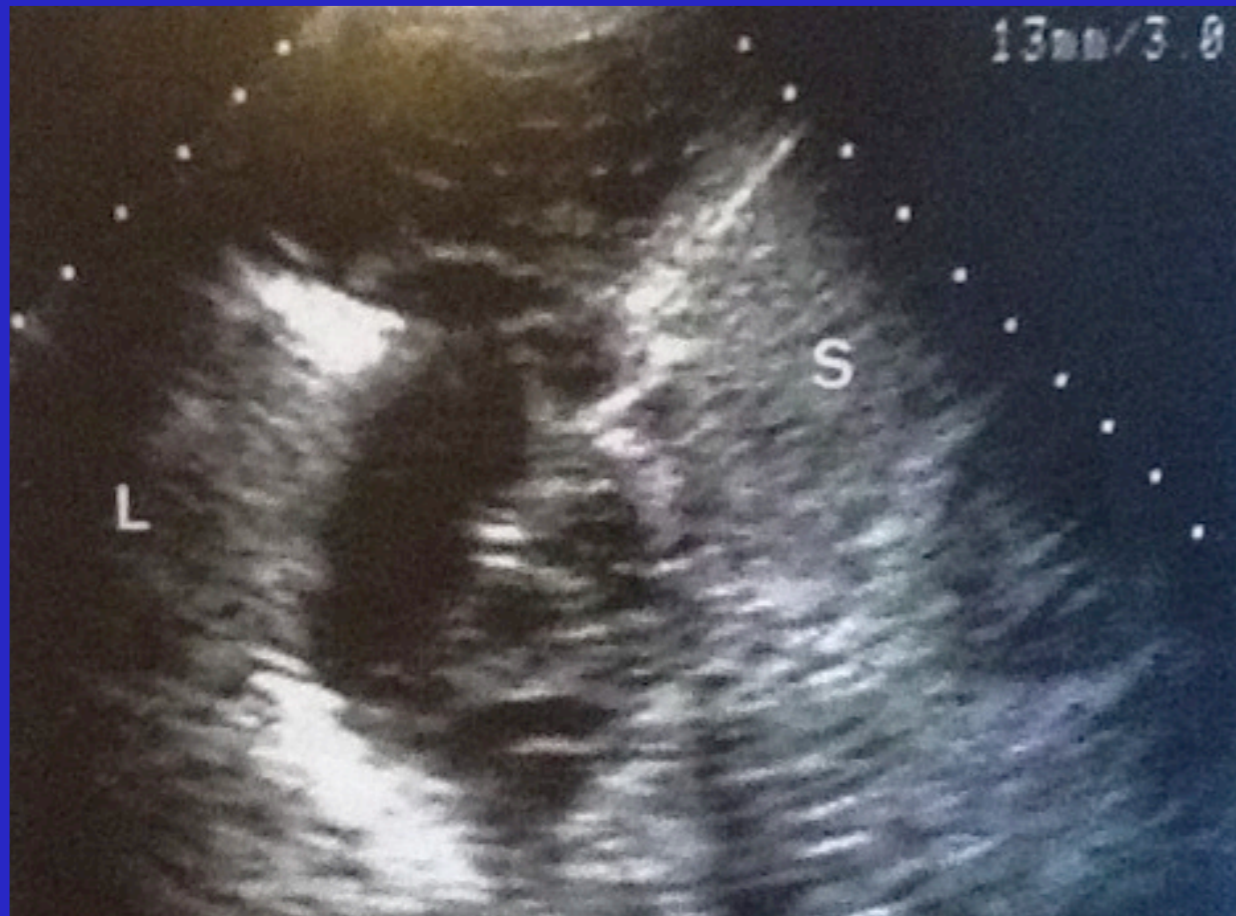No movement, no sinusoid sign



Plankton sign: visualization within tissue like image of a slow whirling movement of numerous particles; hyperechoic structures should correspond to infectious gas; can be seen in hemothorax (should use PLAPS point)

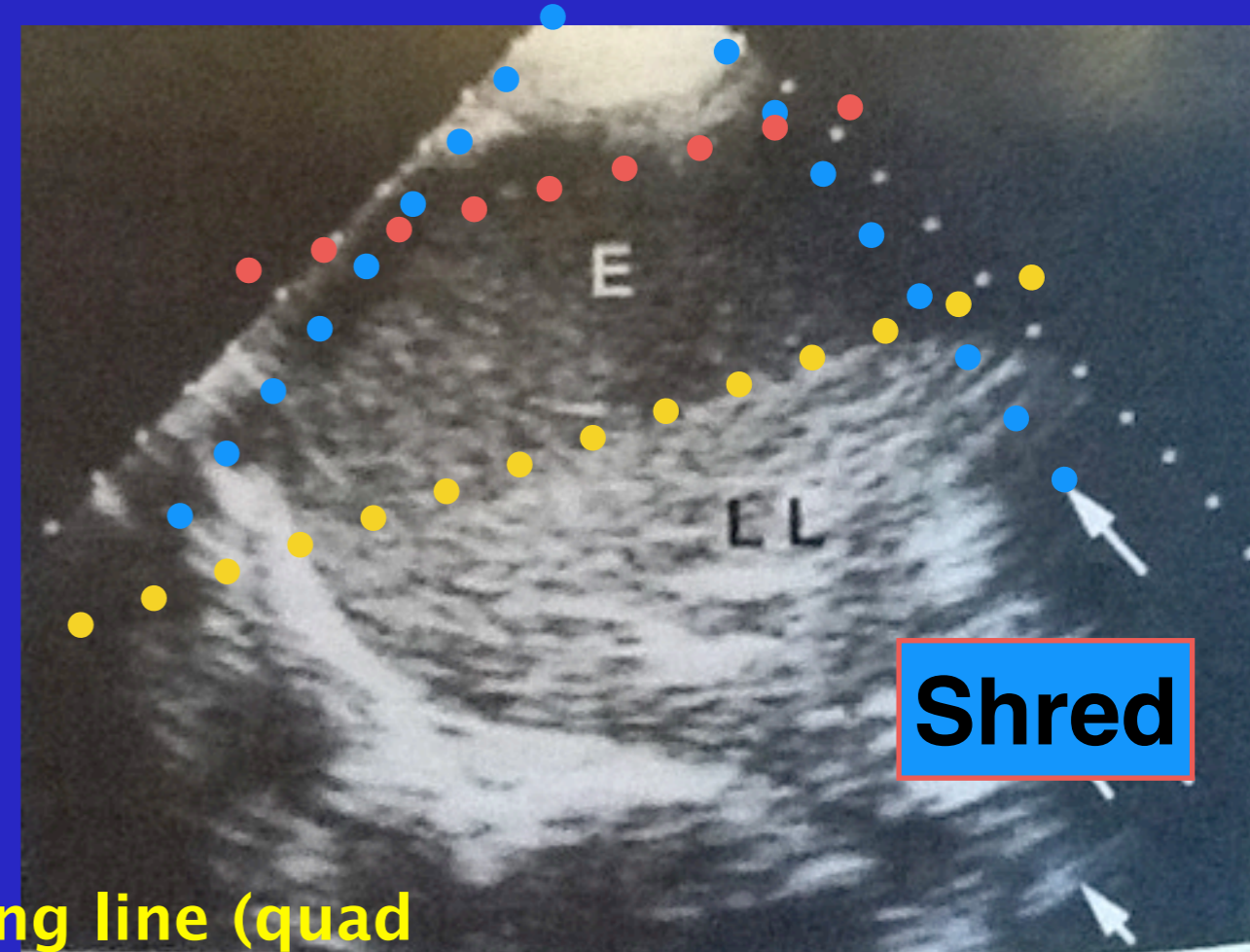
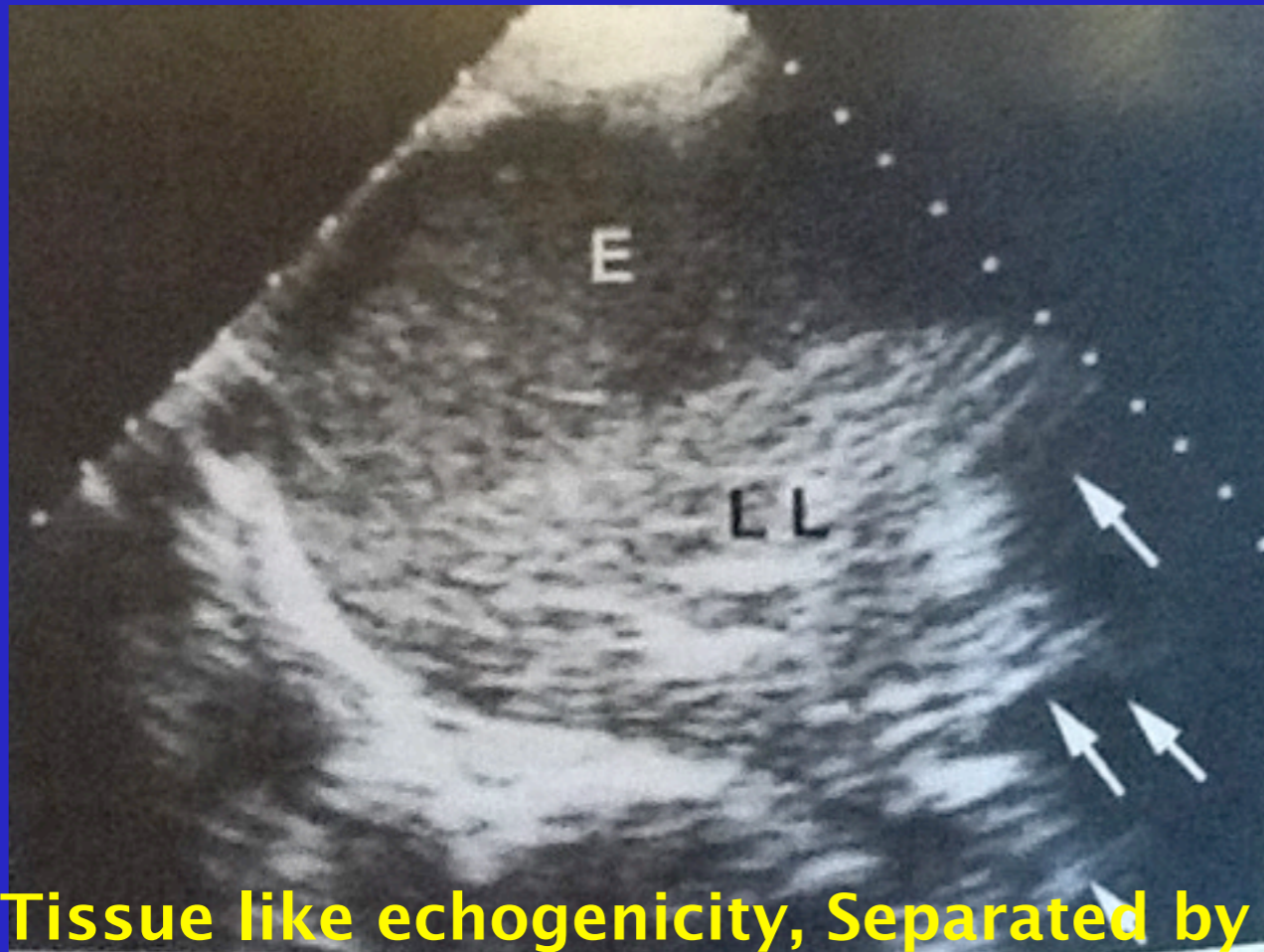Lichtenstein. Textbook. Whole body ultrasonography in the critically ill.

Pleural effusion – are we done?



Lichtenstein. Textbook.
Whole body ultrasonography
in the critically ill.

Pleural effusion – are we done?



Tissue like echogenicity, Separated by lung line (quad sign)

Plankton sign

Shred sign indicating alveolar origin

Hyperechoic points generating dynamic air bronchograms (indicating non atelectatic origin)

Abolished lung sliding, no sinusoid sign, indicate infective process

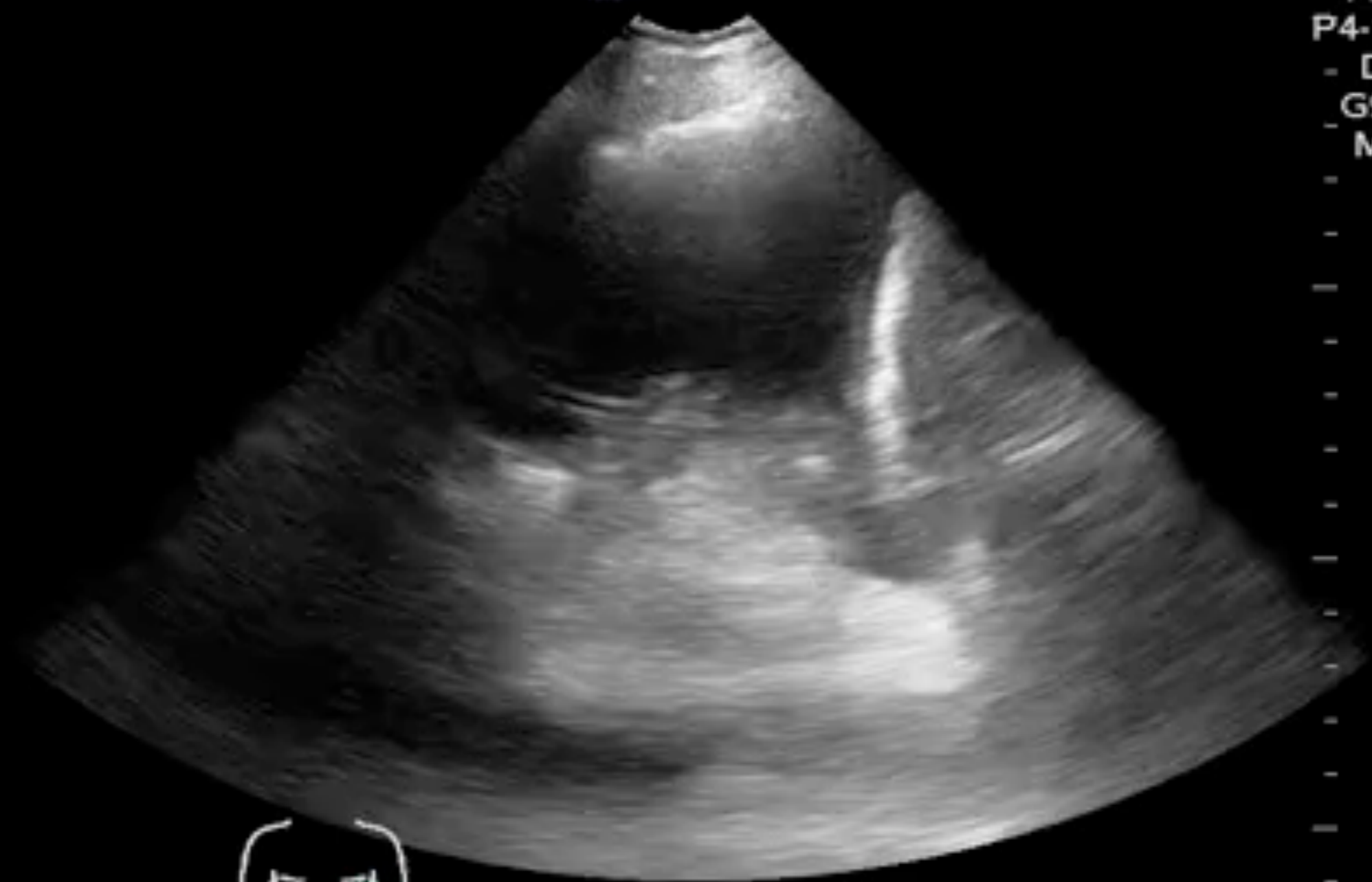Lichtenstein. Textbook.
Whole body ultrasonography
in the critically ill.

SHANDS SOUTH TOWER

ADABAJA 04/19/13
1:07:50 PM

Z

Abd/General
P4-1c/CH4MHz
- DR50/M2/P2
- G90/E1/100%
- MI1.5 TIs0.6
- 16.0 cm
- 19 Hz
△ ZSI -20
Text



Pleural effusion – the numbers

Quad and sinusoid signs confirm presence with 97% with gold standard is withdrawal of fluid; 93% with CT as gold standard

Ultrasound detects effusions occult on radiography; up to 525 mL can be missed on bedside radiograph

Note: effusions allow you to see deep structures like aorta better, consider exploring prior to evacuation

Lichtenstein. Intensive care medicine. 1999

Lichtenstein. Anesthesiology. 2004

Muller. Radiology. 1993

Collins. Radiology. 1972

Pleural effusion – quantity

Minor, moderate, large?...More important might be full clinical state; a diseased lung will not tolerate restrictive syndrome as well

Guidelines?

Several protocols for indicating volume of effusion

PLAPS index: probe at PLAPS point and measuring from pleural line to lung line; probe must be as tangential as possible or will overestimate

Pleural effusion – quantity

Measure on expiration since small effusions will have lung line touch pleural line on inspiration

Usually between 1mm to 4 cm , rarely 5, exceptionally 6, and never 7; a 10 cm value questions technique

PLAPS index

0.3 cm = 15–30 mL

1 cm = 75–150 mL

2 cm = 300–600 mL

3.5 cm = 1500–2500 mL

Pleural effusion – quantity

Limitations: lung floating in early fast effusions, massive consolidation will make lung dive towards earth driving back the pleural effusion

Looking at anterior or phrenic points (usually indicates abundant effusion)

Many other methods

Talmor. Surgery. 1998
Roch. Chest. 2005
Vignon. Crit Care Med. 2005
Balik. Intensive Care Med. 2006

Pleural effusion – technique

1. Presence of quad, sinusoid sign
2. Safety distance of 15 mm seen over three adjacent interspaces
3. Check for absence of interposition of critical structures: lung, aorta, heart, liver, or spleen; move more posterior if lung comes close with inspiration
4. Should be done immediately at time of ultrasound evaluation
5. Technical notes: remember skin folds and not too posterior where dislodgements, infection, decubitus can occur