Ultrasound basics Part 2

'Ultrasound enhanced critical care medicine'

Rohit Patel, MD

University of Florida Health

Director, Critical Care Ultrasound Surgical ICU

Center for Intensive Care

Gainesville, Florida

Critical Care Ultrasound

New **discipline, not same as radiology, cardiology, or even emergency medicine**

New applications *adapted* to use in critical care

Old applications with *point of care* focus

Critical care ultrasound is a *real-time* discipline

Critical Care Ultrasound

A lines Bat sign B lines

B3 lines B7 lines BLUE protocol

BLUE points Comet tails Sinusoid sign

Jellyfish sign Lung point Merlin's space

PLAPS Point Quad sign Seashore sign

Shred sign Stratosphere sign

Tissue like sign Z lines

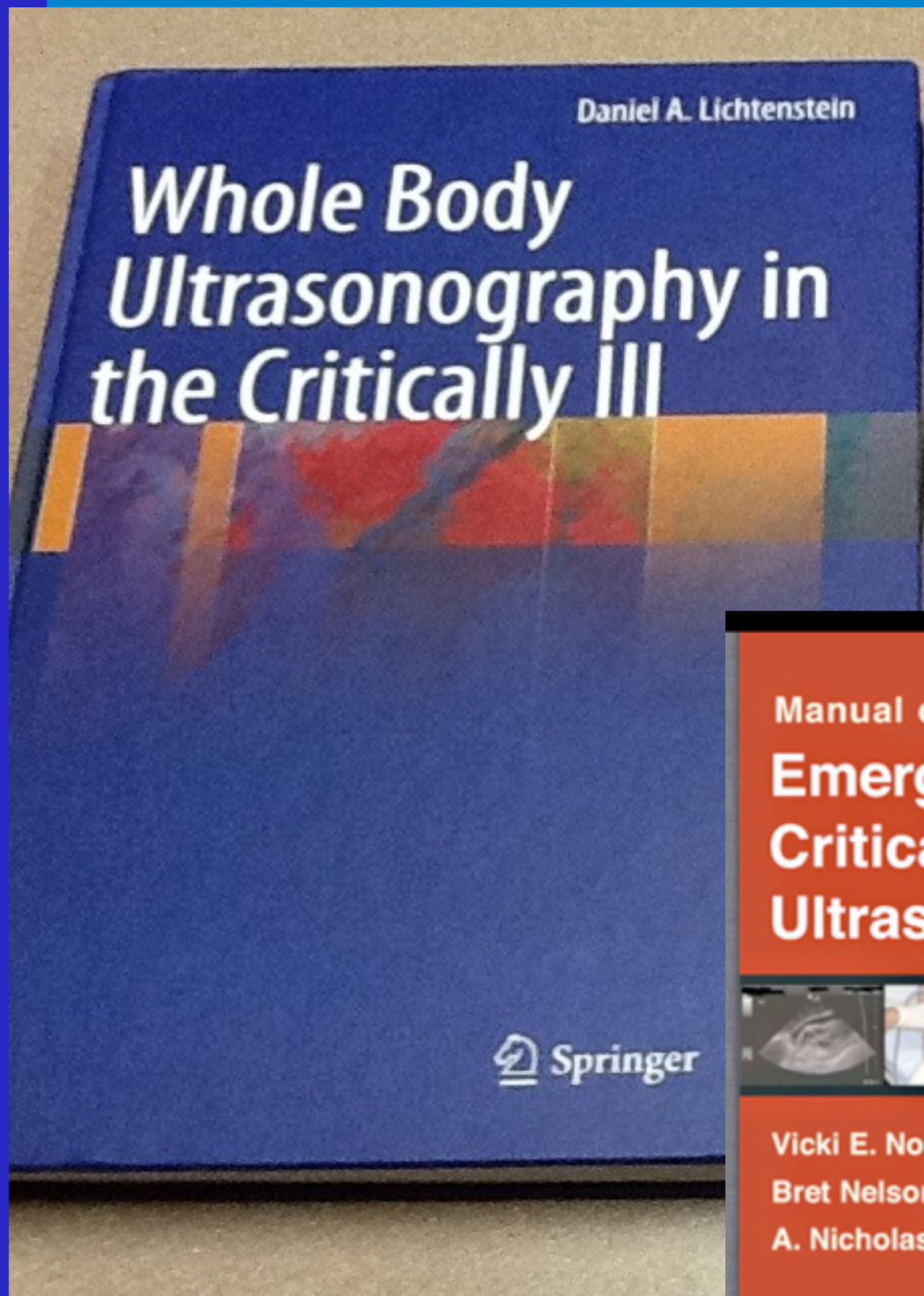
Daniel A. Lichtenstein
Whole Body Ultrasonography in the Critically Ill
Springer

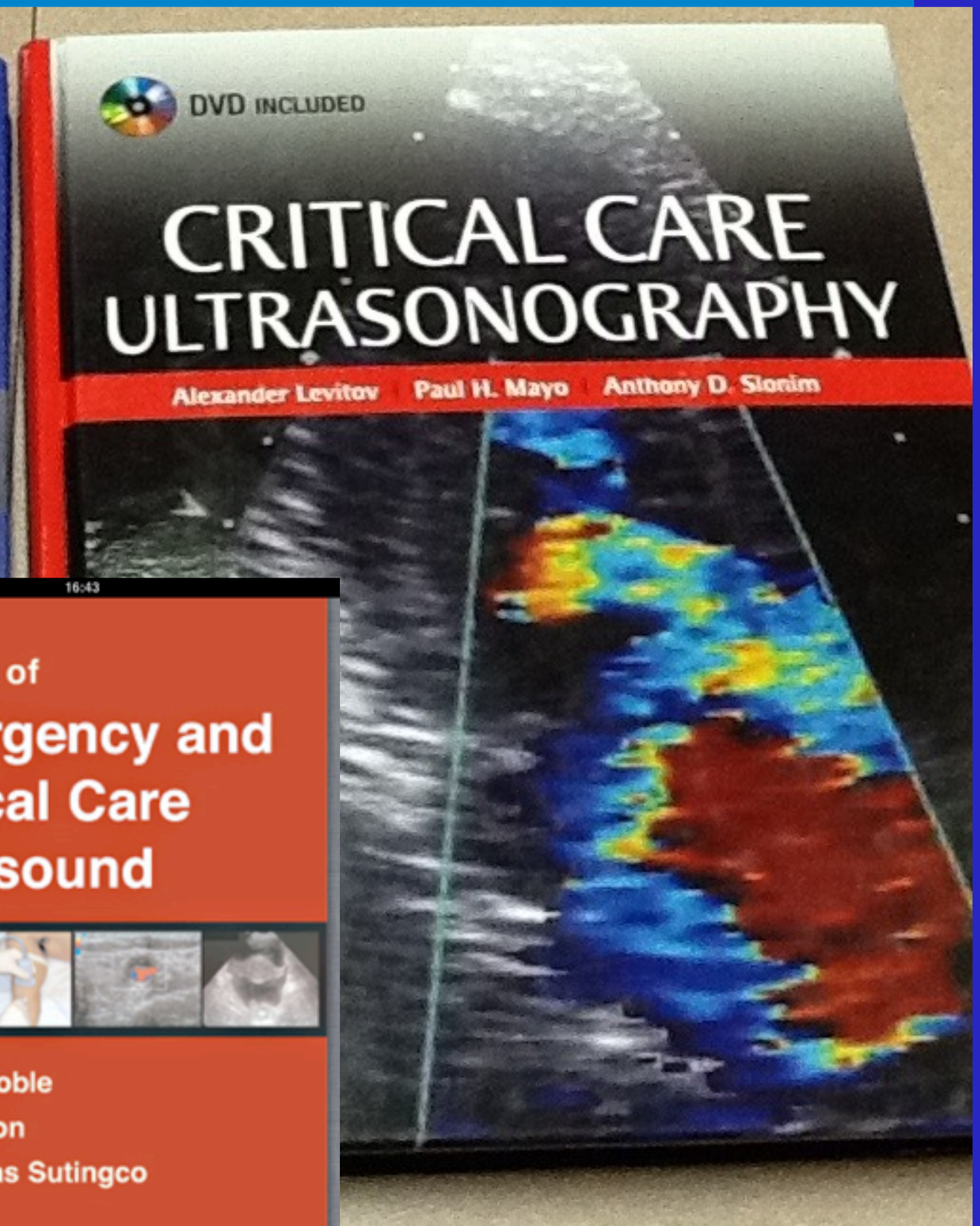
DVD INCLUDED
CRITICAL CARE ULTRASONOGRAPHY
Alexander Levitov
Paul H. Mayo
Anthony D. Slonim

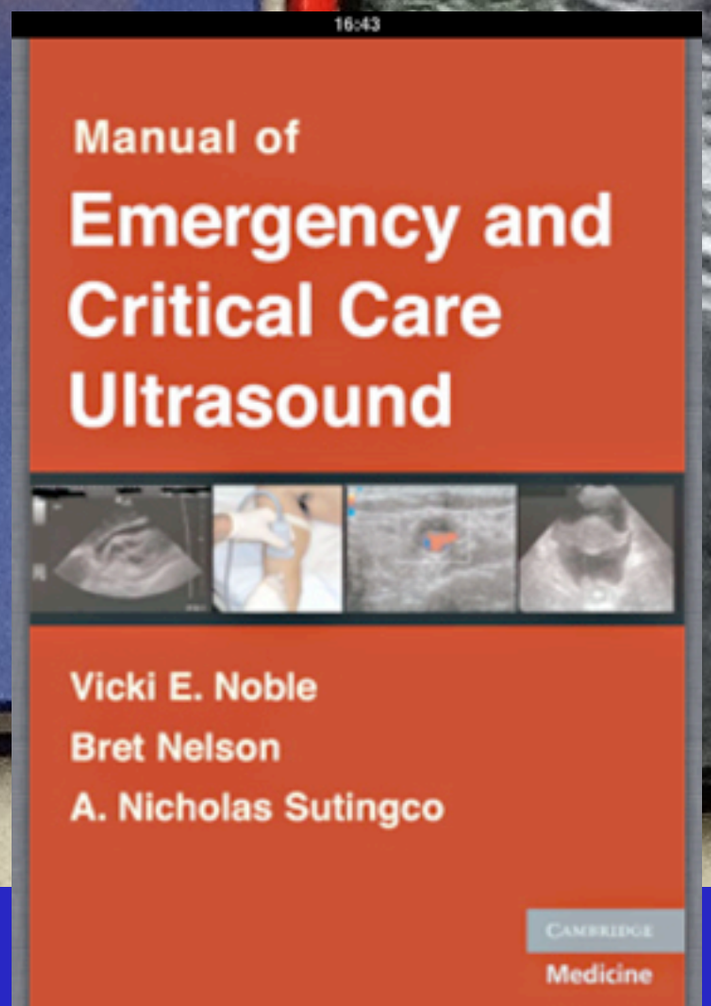
Manual of
Emergency and Critical Care Ultrasound
Vicki E. Noble
Bret Nelson
A. Nicholas Sutingco
Cambridge
Medicine

How to learn ICU ultrasound

Similar to how you learned physical exam skills

Pick one application or even part of an application (like how to evaluate for pneumothorax, or how to evaluate left ventricle function) and then focus only on that, find a bunch of normals, then when you hear of abnormal ones go and find it yourself

We do not suddenly become sonographers just like we don't suddenly become intensivists

How to learn ICU ultrasound

First step: once you learn to interpret lung sliding in normal patients, find a patient with confirmed pneumothorax and find the stratosphere sign.

Second step: now search for stratosphere sign in a patient with an acute problem but manage as you normally would (CT, etc) and thereby build your confidence

Third step: now facing a similar patient but no time for CT, finding lung sliding (not putting in chest tube) and driving your thought process in other direction

How to learn ICU ultrasound

Wild ultrasound

Working a night shift on a crashing patient and using it with your known limitations

Barely remembering one or two lectures about a specific topic

The ultrasound equipment

New machines does not equal better; not specifically designed for critical care and one of the most vital organs the lung

Small machines not necessarily more convenient

We need ultrasound <u>dedicated</u> to critical care: small width to go between ventilator, IV poles, etc; compact design with minimal nooks to clean easily between pts, short start up time, one microconvex probe, no Doppler

Who should get ultrasound?

In France: everyone at first admission to ICU and then subsequent specific problems

In ICU, folks who are ***hypotensive or hypoxic*** probably benefit most (few algorithms developed to evaluate these events)

On the horizon: Fever, cardiac arrest, oligoanuric, sepsis, ARDS, difficult airway, weaning from mechanical ventilation, abdominal pain

Table 3.2 Usual report of whole-body critical ultrasound

Hôpital Service de
Ambroise-Paré Réanimation Médicale
ULTRASOUND REPORT
Urgent/Scheduled
Name Day **DATE 2010** Hour
D. Lichtenstein Unit: Hitachi EUB-405 – 5-MHz microconvex probe Birth date Setting Day XX
Clinical question:
Conditions, patient's echogenicity: correct OR ELSE
Ventilatory status and position: mechanical/spontaneous ventilation Tidal volume PEEP 02 Eupnea/dyspnea Patient no
sedated not or curarized supine position semi recumbent armchair other
Various items for research design (auscultation data, description of radiography, etc.)
Thorax
Right lung
- stage 1 analysis:
- Upper BLUE point:
- peak lung sliding: present abolished
- artifacts: A-predominance or B-predominance ORxELSE
- Lower BLUE point: same items
- stage 2 analysis:
- lateral: B-lines ORxELSE
- pleural effusion:
- alveolar consolidation:
- phrenic point: Cupola: eutopic ORxELSE. Amplitude xxx mm
- stage 3 analysis:
- PLAPS point: PLAPS (+ details) or not – ORxELSE
- stage 4 analysis:
- apex analysis:
- comprehensive posterior scanning:
- free text
Left lung
- same items
Mediastinum
Thoracic aorta (initial, arch, descending aorta): normal ORxELSE
Right pulmonary artery: visible ORxELSE
Superior caval vein: visible ORxELSE Expiratory mediolateral caliper Inspiratory c
Heart (two-dimensional approach). Easy examination ORxELSE
Pericardium: sub-normal ORxELSE
Left ventricle: free text
- diastolic caliper – systolic caliper
- i.e.: global contractility: low normal exaggerated
- dilatation: absent moderate substantial
Right ventricle: free text
- volume: normal or enlarged
- free wall: thin thick ORxELSE
- contractility
Other elements: free text
Deep veins
Two-dimensional, short-axis, controlled compression method
Internal jugular (dominant: right or left): free ORxELSE
Subclavian: free ORxELSE
IVC: correct exploration, empty vessel ORxELSE
Iliac: correct exploration, empty vessel ORxELSE
Femoral: free ORxELSE
Popliteal: free ORxELSE
Calf: at least partially (%) compressible ORxELSE
Head
Right (left) optic nerve: Caliper xxx (hM) Micro-bulging: yes/no Sinuosity checked: yes/no
Maxillary sinus (supine/erect patient) (nasogastric probe: yes/no) **Right (left)**
complete OR incomplete

Table 3.2 (continued)

Abdomen
Examination: optimal/suboptimal (reasons: body habitus, gas, dressings, others)Fluid peritoneal effusion: absent ORxELSE
Pneumoperitoneum: absent (gut sliding present and/or splanchnogram) ORxELSE
Stomac: full empty gastric probe visible in situ ORxELSE
Small bowel: peristalsis present or abolished or not accessible Wall: thin ORxELSE Caliper: normal ORxELSE
Contents: anechoic or echoic Unaccessible bowel
Colon Same items Search for air–fluid levels
Aorta: regular ORxELSE
Inferior caval vein: Expiratory size at the left renal vein = xxx mm Patency :
Adrenal: analyzed ORxELSE
Kidneys: nondilated pelvis ORxELSE
Bladder: full empty correctly drained Uterus:
Gallbladder: No elective pain Not enlarged (nn × nn mm) Wall not thickened (mm) Wall regular homogeneous Contents anechoic, or sludge (%) No satellite peritoneal effusion ORxABSENCExOF THESExITEMS
Liver: no visible acute anomaly – no portal gas – on comprehensive or limited examination ORxELSE
Biliary tract: fine ORxELSE
Spleen: normal size ORxELSE Homogeneous pattern ORxELSE
Portal system: no anomaly ORxELSE
Pancreas: normal in size and echostructure ORxELSE
Retroperitoneum: analyzed ORxELSE
Other remarkable elements seen:
Miscellaneous
Musculo-fat ratio. Thickness of the crural muscle (right thigh):
SYNTHESIS
A practical synthesis is written (time permitting) in a style allowing any physician, even without ultrasound culture, to understand the main points of the clinical situation. It focuses on immediate management changes.

Ultrasound Physics



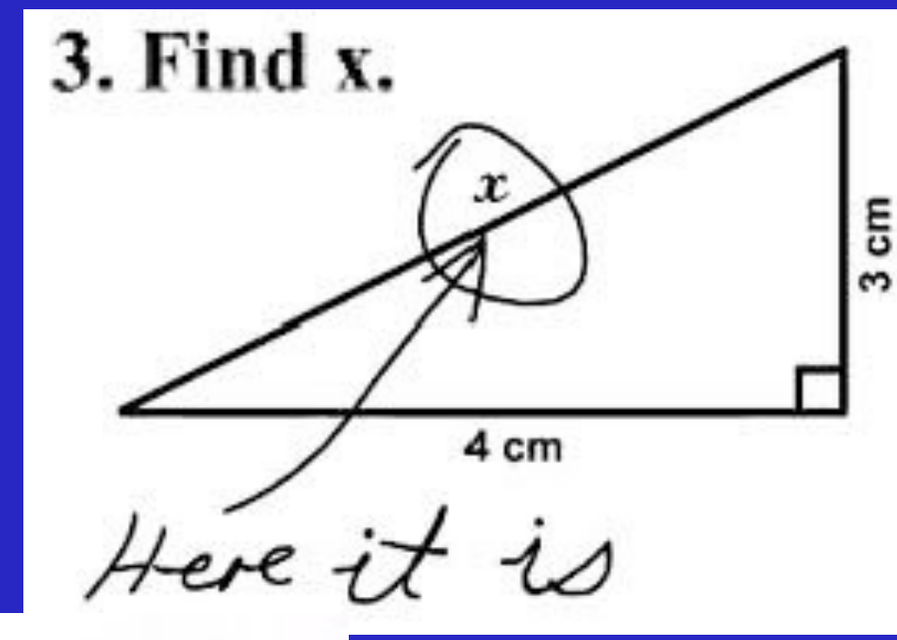

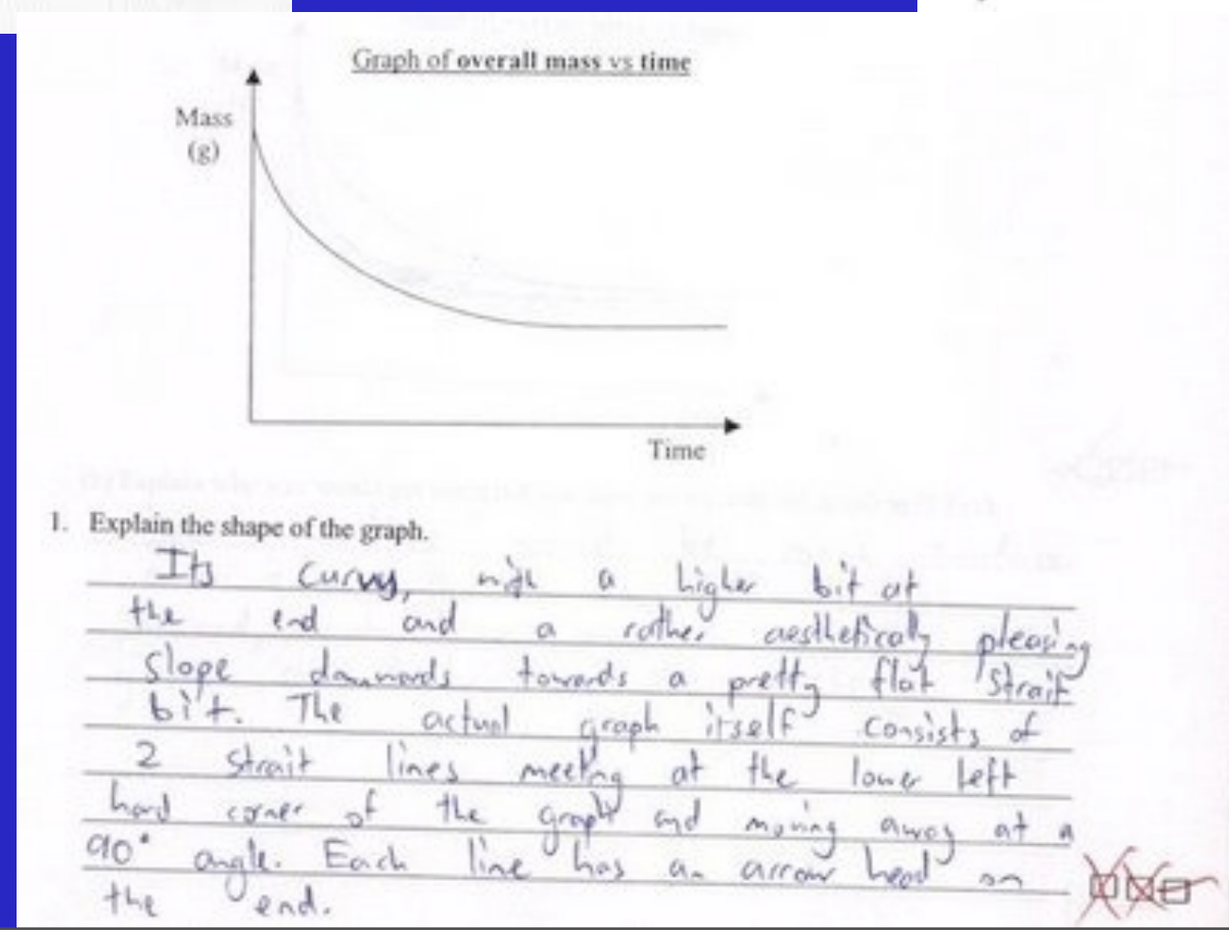

Definitions and physics

Amplitude

Velocity

Frequency

Wavelength

Attenuation

Reflection, refraction, scattering, resolution

Acoustic power

Definitions and physics

Amplitude

hyperechoic and hypoechoic

Equals peak pressure of wave

'loudness of sound'

Correlates with intensity of returning echo

Understanding composition of image

Basic glossary: all the 'echoics'

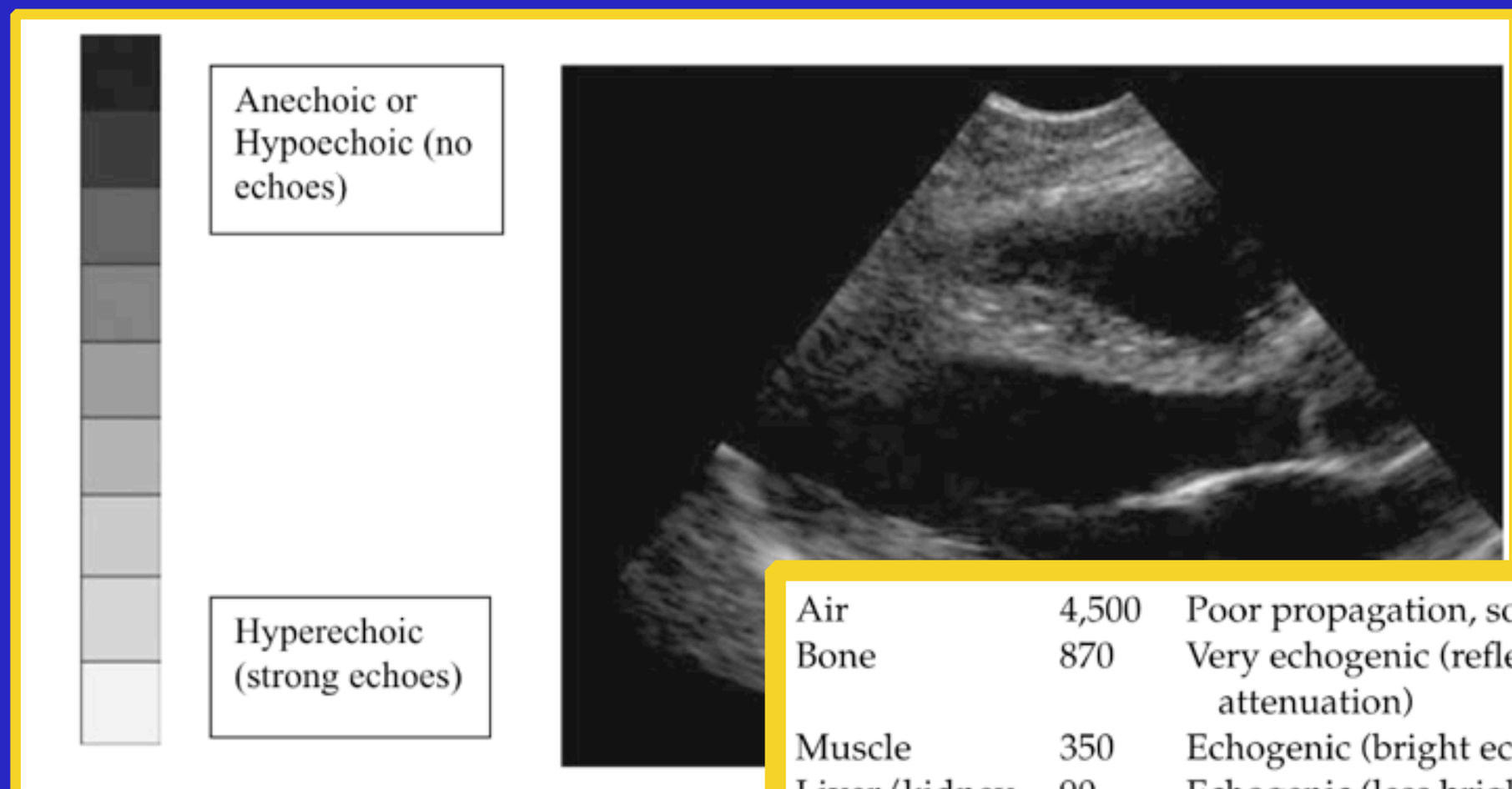

Air	4,500	Poor propagation, sound waves often scattered
Bone	870	Very echogenic (reflects most back, high attenuation)
Muscle	350	Echogenic (bright echo)
Liver/kidney	90	Echogenic (less bright)
Fat	60	Hypoechoic (dark echo)
Blood	9	Hypoechoic (very dark echo)
Fluid	6	Hypoechoic (very dark echo, low attenuation)

Levitov. Critical Care Ultrasonography textbook. 2009.

Definitions and physics

Velocity

speed of wave

1540 m/s in soft tissue

Ultrasound can use this to determine depth of structure

Like sonar use in submarines

Definitions and physics

Frequency:

Number of waves per cycle (cycles per second)

High frequency uses more energy so less penetration

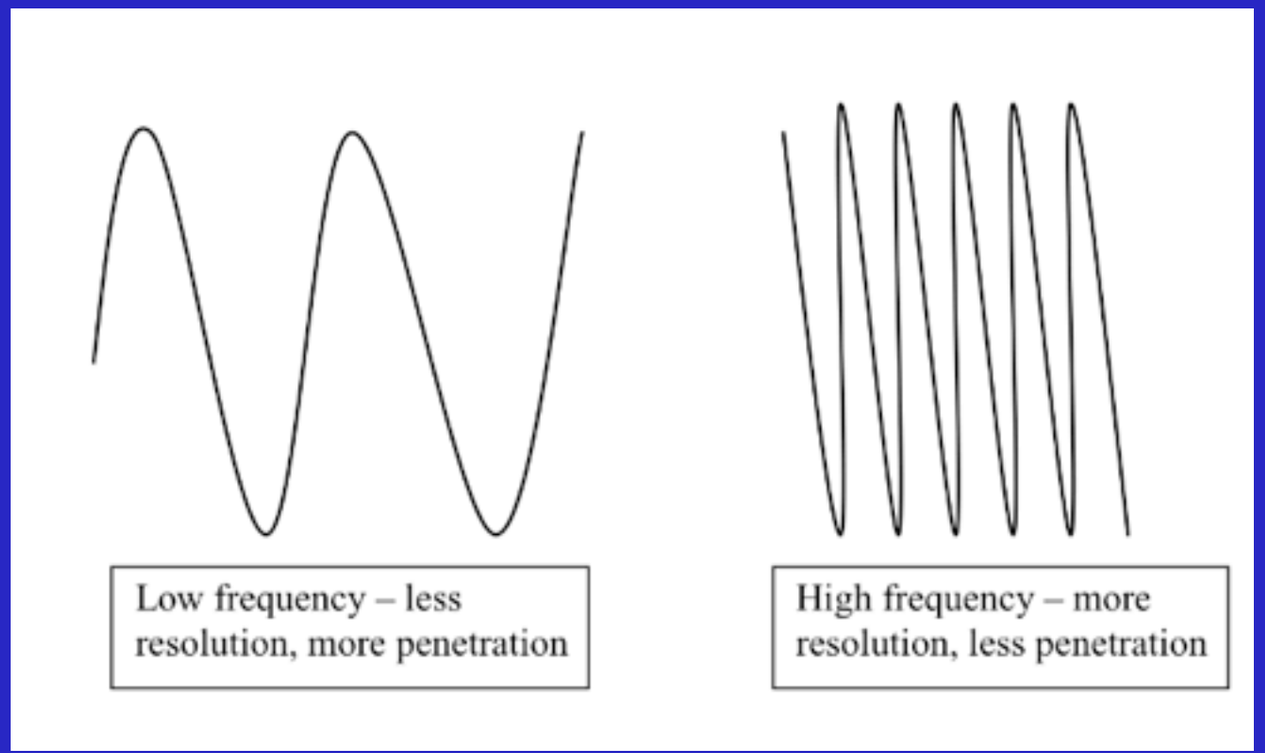

Levitov. Critical Care Ultrasonography textbook. 2009.

Definitions and physics

Wavelength

distance wave travels in one cycle

Definitions and physics

Attenuation

progressive weakening of sound wave through medium

Many factors affect: type of medium, number of interfaces

air is strong reflector and does not transmit

bone high attenuation

fat or fluid would be less attenuation

Definitions and physics

Reflection = redirection of part of sound wave back to source

Refraction = redirection of part of sound wave as it crosses different media

Scattering = when sound beam encounters a smaller or irregular shape

Absorption = when acoustic energy of sound wave is contained within medium

Resolution = ultrasound machines ability to discriminate between two close objects

Definitions and physics

Acoustic power

energy leaving transducer

ALARA = As Low As Reasonably Acceptable

Therapeutic is whole new lecture!

Few Points about Doppler

used to detect speed, presence of flow, and direction of flow

sound moves away from observer, frequency will decrease

‘positive doppler shift’ means blood flowing towards probe

doppler most accurate when angle of beam is parallel (like in apical heart view)

red means towards probe, blue means away (not red = artery, blue = vein)

velocity scale needs to be set low if looking for low velocity (like veins) (use the gain buttons with in color doppler mode)

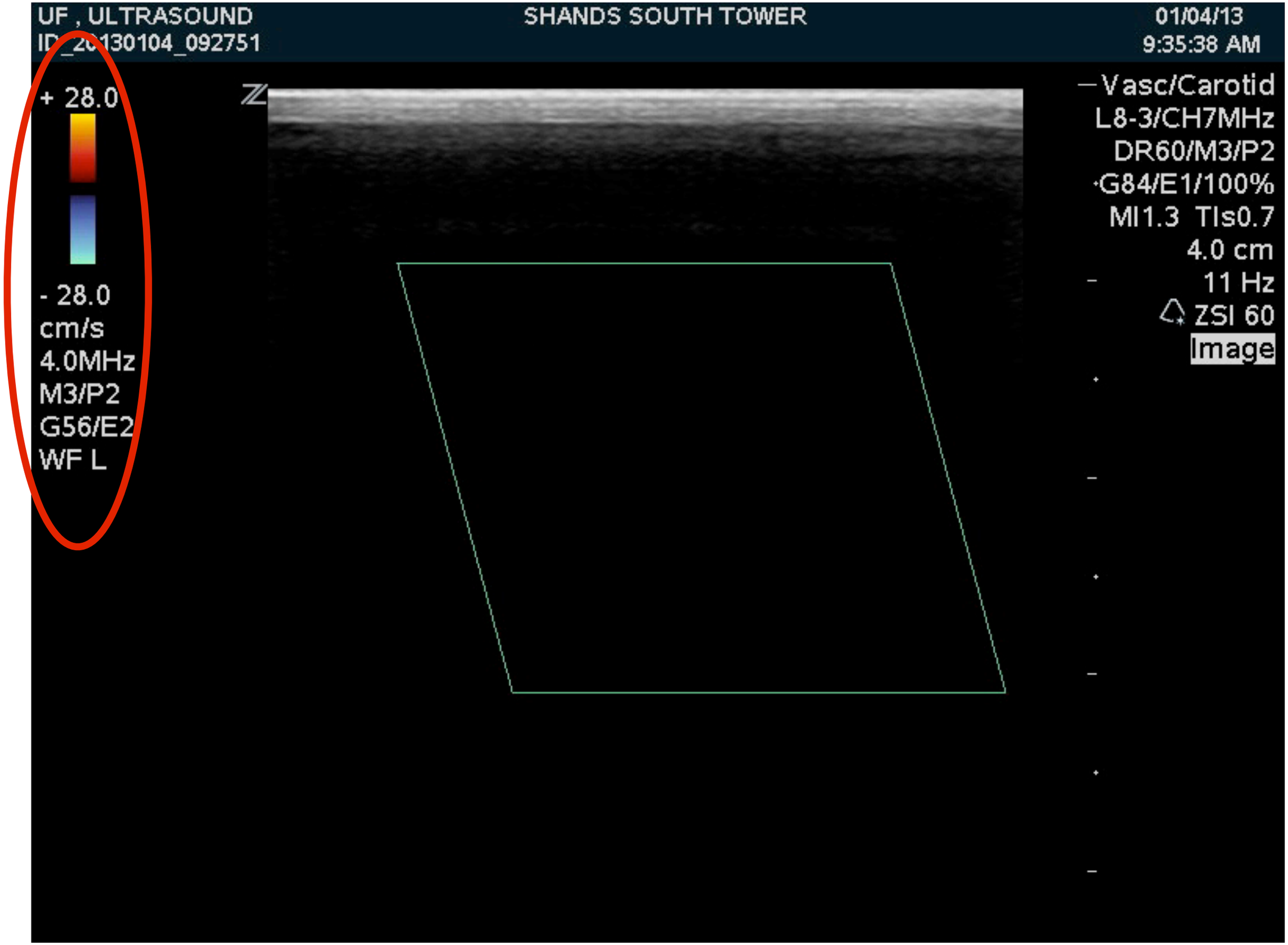
UF , ULTRASOUND
ID_20130104_092751
SHANDS SOUTH TOWER
01/04/13
9:35:38 AM
+ 28.0
- 28.0
cm/s
4.0MHz
M3/P2
G56/E2
WF L
Vasc/Carotid
L8-3/CH7MHz
DR60/M3/P2
G84/E1/100%
MI1.3 TIs0.7
4.0 cm
11 Hz
ZSI 60
Image

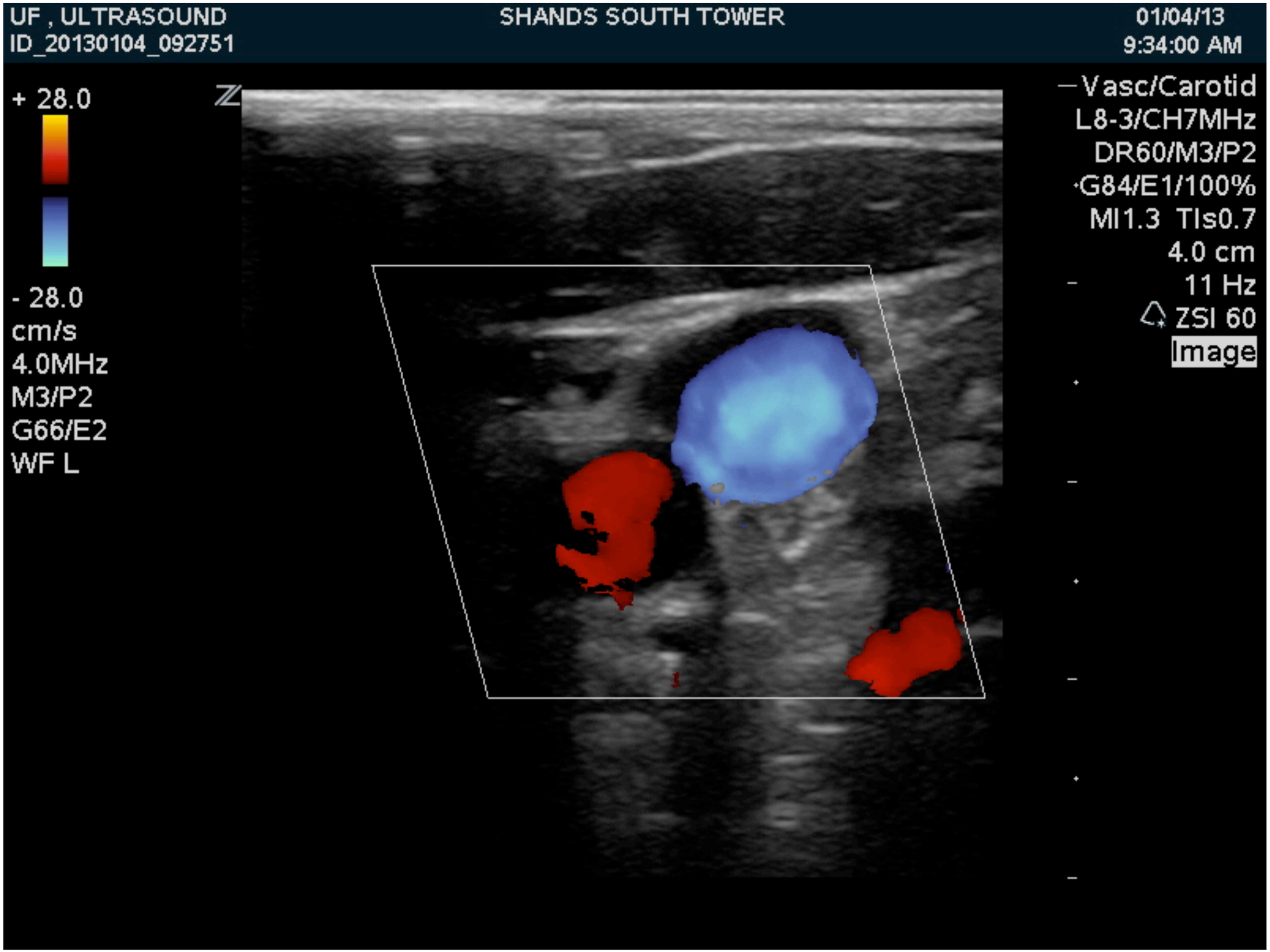
UF , ULTRASOUND
ID_20130104_092751
SHANDS SOUTH TOWER
01/04/13
9:34:00 AM
+ 28.0
- 28.0
cm/s
4.0MHz
M3/P2
G66/E2
WF L
Vasc/Carotid
L8-3/CH7MHz
DR60/M3/P2
G84/E1/100%
MI1.3 TIs0.7
4.0 cm
11 Hz
ZSI 60
Image

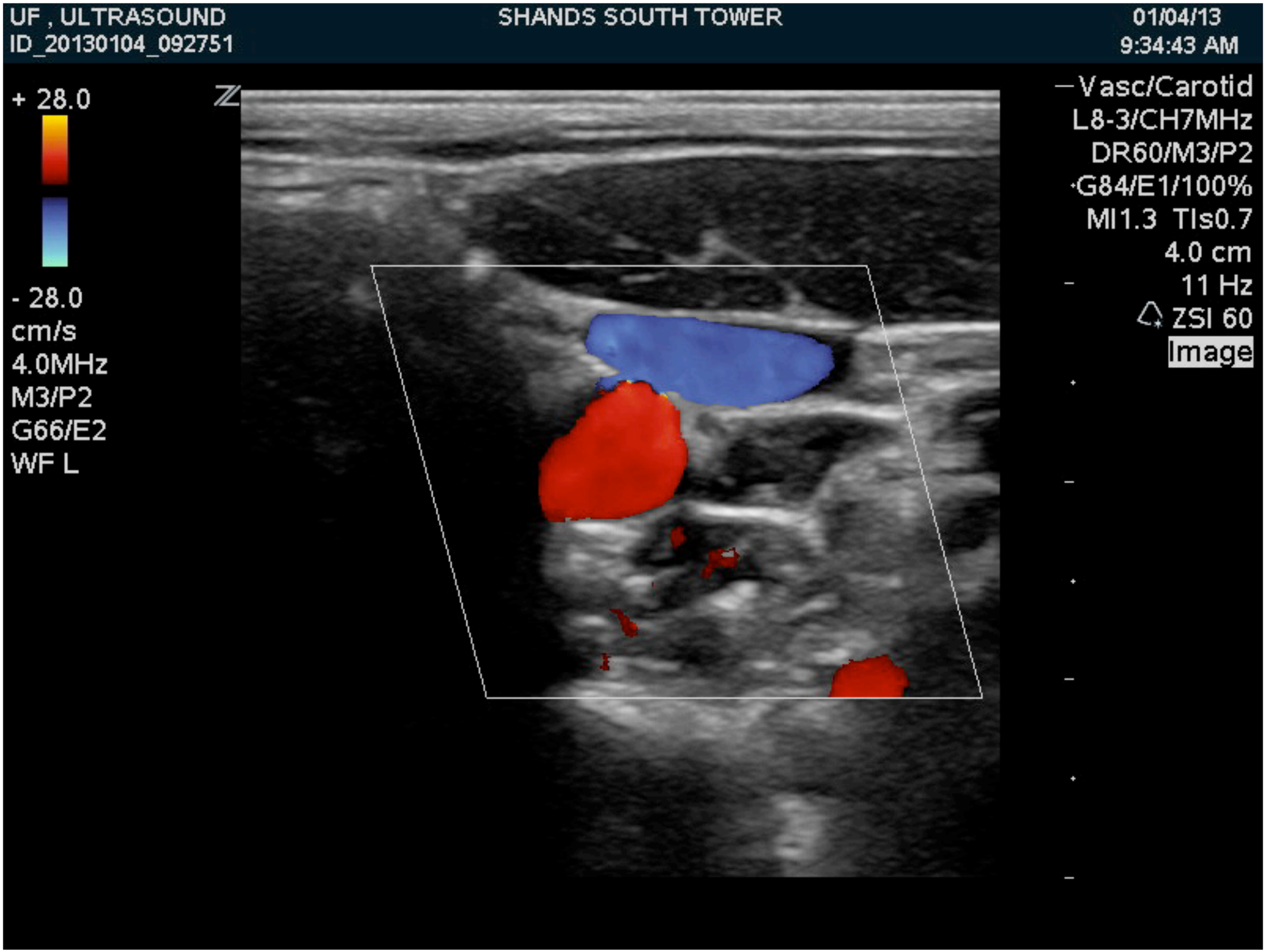
UF , ULTRASOUND
ID_20130104_092751
SHANDS SOUTH TOWER
01/04/13
9:34:43 AM
+ 28.0
- 28.0
cm/s
4.0MHz
M3/P2
G66/E2
WF L
Vasc/Carotid
L8-3/CH7MHz
DR60/M3/P2
G84/E1/100%
MI1.3 TIs0.7
4.0 cm
11 Hz
ZSI 60
Image

PROBE HERE

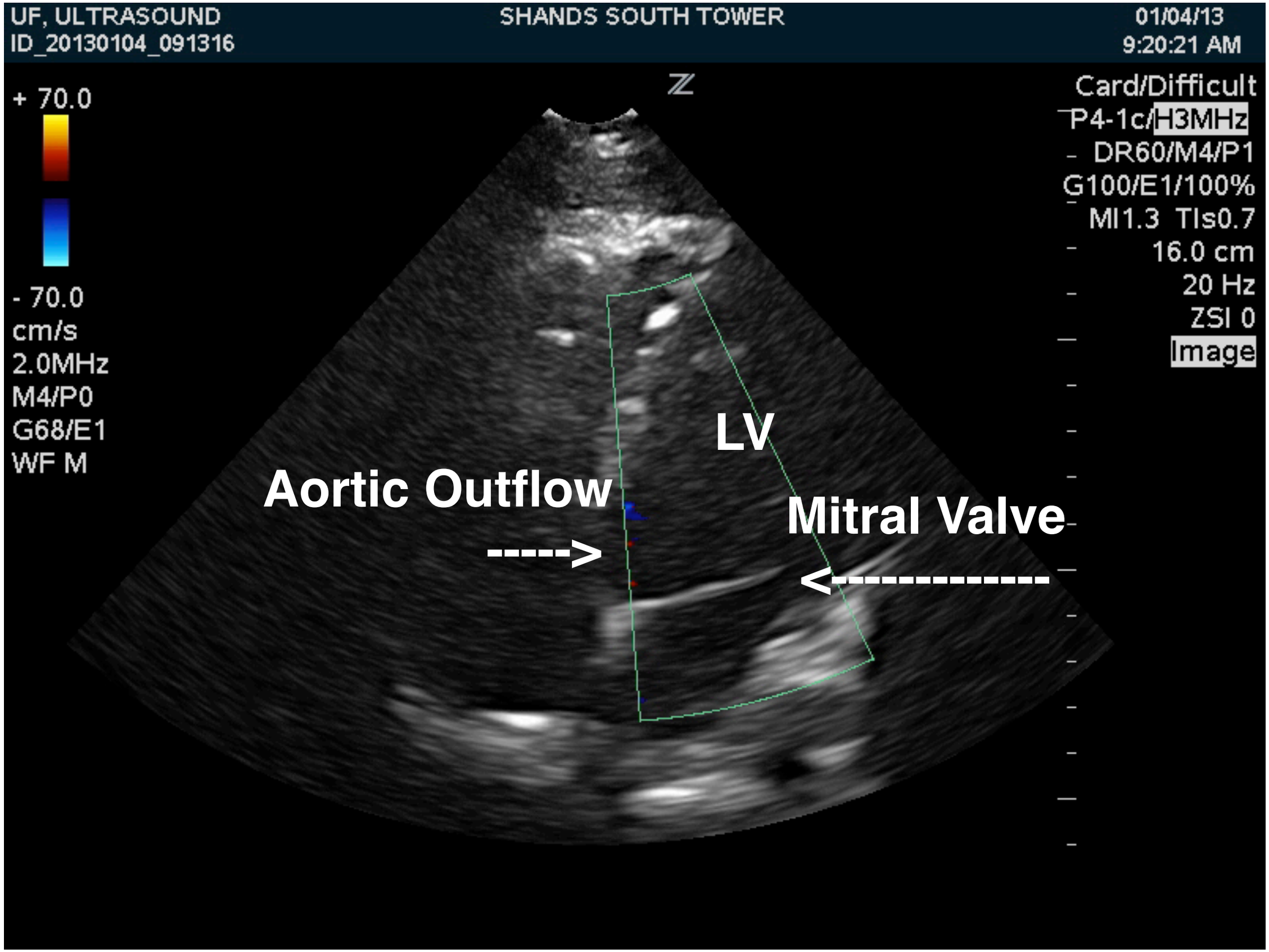
UF, ULTRASOUND
ID_20130104_091316
SHANDS SOUTH TOWER
01/04/13
9:20:21 AM
+ 70.0
- 70.0
cm/s
2.0MHz
M4/P0
G68/E1
WF M
Card/Difficult
P4-1c/H3MHz
DR60/M4/P1
G100/E1/100%
MI1.3 TIs0.7
16.0 cm
20 Hz
ZSI 0
Image
LV
Aortic Outflow
----->
Mitral Valve
<----------

Interpretation of image

Reading literature

Operator's familiarity with own field (without ultrasound)

Practice, practice, practice just like any other procedure