

TIP SHEET: .USFAST (CPT 76604, 76705)

Indication: trauma ultrasound for suspicion of intraperitoneal hemorrhage, pericardial tamponade, and/or hemothorax

Questions to ask yourself:

- Pericardial Fluid: YES or NO
- Hepatorenal fluid: YES or NO
- Splenorenal fluid: YES or NO
- Rectovesical fluid: YES or NO

Extended FAST: for pneumothorax and hemothorax
Hemothorax: YES or NO or INDETERMINATE
Lung sliding: PRESENT or ABSENT
M-Mode: Seashore sign or Stratosphere sign

Images you should obtain:

Probe: Low Frequency Phased Array & High Frequency Linear Array for pneumothorax

- FAST1 – Subxiphoid or Parasternal
- FAST2 – Right Upper Quadrant (Hepatorenal)
- FAST3 – Left Upper Quadrant (Splenorenal)
- FAST4 – Rectovesicular space
- EFAST1 – Right M-mode image (for Pneumothorax)
- EFAST1.1 – Left M-mode image (for Pneumothorax)
- EFAST2 – Right Lateral/Posterior Lung (for Hemothorax)
- EFAST2.1 – Left Lateral/Posterior Lung (for Hemothorax)

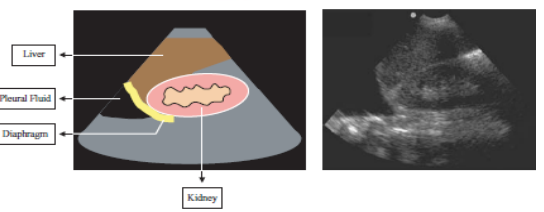
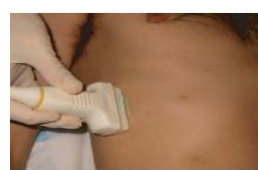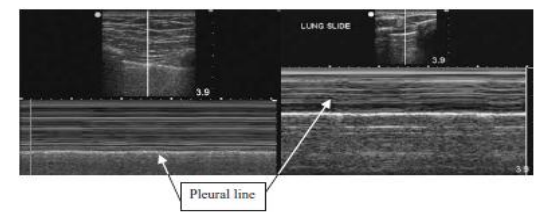
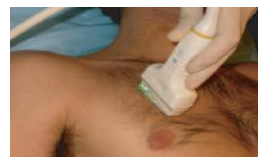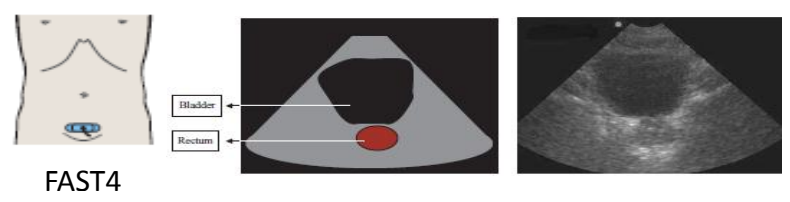
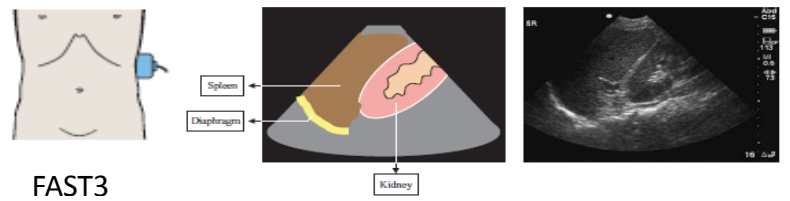
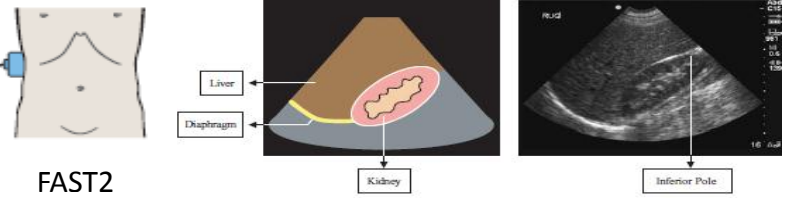
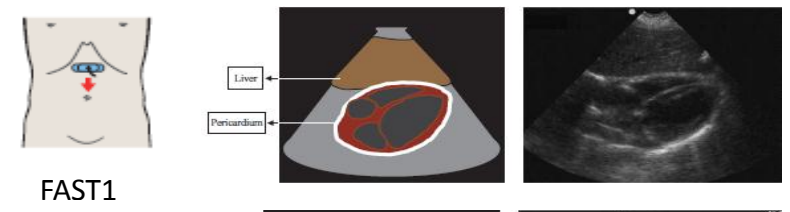
Scanning Tips:

Hepatorenal view:

Ribs in way? Try turning probe clockwise or counterclockwise slightly or have patient take deep breath
Can't locate diaphragm? Try bringing probe lower on abdominal wall towards stretcher or slide up or down towards head/feet to get something familiar in view

Splenorenal view:

Ribs in way? Same as above and sometimes because spleen is smaller than liver can see through anterior view
Can't locate diaphragm? Almost always have to start with hand of probe depressed in bed, start there and then go more anterior



Pelvis view:

Can't find bladder? Most commonly probe too cephalad, move lower down and angle towards feet. If foley is in place can either wait til some fluid is given or can put saline into foley

Cardiac View:

Can't find heart? Most often probe is too steep in subxiphoid view, depth on machine might be too shallow, or swallowed too much air and trying to look through gastric air. If air is the problem, try looking through the liver, or change view to parasternals

Lung views for pneumothorax and hemothorax:

Can't see pleural line? If unable to locate anything might have subcutaneous air, try different lung positions.
Can't see above diaphragm? Try positioning more posterior and slide probe up towards head