

## Lung ultrasound in diagnosing and monitoring pulmonary interstitial fluid

### *Ecografia polmonare nella diagnosi e nel monitoraggio dei fluidi interstiziali polmonari*

G. Volpicelli<sup>1</sup> · L.A. Melniker<sup>2</sup> · L. Cardinale<sup>3</sup> · A. Lamorte<sup>1</sup> · M.F. Frascisco<sup>1</sup>

<sup>1</sup>Department of Emergency Medicine, San Luigi Gonzaga University Hospital, Torino, Italy

<sup>2</sup>Department of Emergency Medicine, New York Methodist Hospital, NY, USA

<sup>3</sup>Institute of Radiology, San Luigi Gonzaga University Hospital, Torino, Italy

Correspondence to: L. Cardinale, S.C.D.U. Radiologia, Ospedale San Luigi Gonzaga, Regione Gonzole 10, Orbassano, 10040 Torino, Italy, e-mail: luciano.cardinale@gmail.com

Received: 7 July 2011 / Accepted: 26 October 2011

© Springer-Verlag 2012

#### Abstract

Chronic heart failure is a complex clinical syndrome often characterised by recurrent episodes of acute decompensation. This is acknowledged as a major public health problem, leading to a steadily increasing number of hospitalisations in developed countries. In decompensated heart failure, the redistribution of fluids into the pulmonary vascular bed leads to respiratory failure, a common cause of presentation to the emergency department. The ability to diagnose, quantify and monitor pulmonary congestion is particularly important in managing the disease. Lung ultrasound (US) is a relatively new method that has gained a growing acceptance as a bedside diagnostic tool to assess pulmonary interstitial fluid and alveolar oedema. The latest developments in lung US are not because of technological advance but are based on new applications and discovering the meanings of specific sonographic artefacts designated as B-lines. Real-time sonography of the lung targeted to detection of B-lines allows bedside diagnosis of respiratory failure due to impairment of cardiac function, as well as quantification and monitoring of pulmonary interstitial fluid. Lung US saves time and cost, provides immediate information to the clinician and relies on very easy-to-acquire and highly reproducible data.

**Keyword** Heart failure · Pulmonary congestion · Pulmonary interstitial fluid · Lung ultrasound · Respiratory failure

#### Riassunto

L'insufficienza cardiaca cronica è una complessa sindrome clinica caratterizzata spesso da episodi ricorrenti di scompenso acuto. Tale condizione rappresenta uno dei maggiori problemi di salute pubblica, che porta ad un numero sempre crescente di ospedalizzazione nei paesi più sviluppati. Nella insufficienza cardiaca scompensata, la redistribuzione dei fluidi nel letto vascolare polmonare comporta l'insufficienza respiratoria, una causa comune di presentazione nel Dipartimento di Emergenza. La capacità di diagnosticare, quantificare e monitorare la congestione polmonare è di particolare importanza nel trattamento di questa malattia. L'ecografia polmonare è un metodo relativamente nuovo, oramai sempre più diffusamente riconosciuto come mezzo diagnostico utile per la valutazione dell'edema interstiziale ed alveolare al letto del paziente. Il recente sviluppo dell'ecografia polmonare non è legato allo sviluppo tecnologico, ma è basato sulle nuove applicazioni e sulla scoperta del significato di specifici artefatti ecografici chiamati linee B. L'ecografia polmonare mirata alla identificazione delle linee B permette la diagnosi al letto del paziente in tempo reale dell'insufficienza respiratoria dovuta a scompenso cardiaco, così come la quantificazione ed il monitoraggio della congestione polmonare. La tecnica ecografica polmonare riduce i tempi ed i costi diagnostici, e si basa su segni semplici da identificare ed altamente riproducibili che forniscono immediate informazioni nella gestione del paziente.

*Parole chiave* Insufficienza cardiac · Congestione polmonare · Fluidi interstiziali polmonari · Ecografia polmonare · Insufficienza respiratoria

## Congestion in heart failure

Exacerbation of heart failure is a complex condition, the main feature of which is haemodynamic pressure overload. When excess fluid is redistributed within the lungs, congestion results in interstitial and alveolar oedema, causing what is commonly named pulmonary congestion [1, 2]. Invasive measurement of pressure across pulmonary capillaries by a pulmonary artery catheter, the pulmonary capillary wedge pressure (PCWP), represents a good estimate of pressure overload due to congestive heart failure [3, 4]. High PCWP values accurately predict decompensation in patients with heart failure. Another important sign of decompensation is high values of cardiac left ventricular filling pressure (LVFP), which usually indicates lung redistribution of fluids, which can be the first step towards the development of pulmonary oedema. Therefore, PCWP and LVFP are two important parameters in the diagnosis and follow-up of heart failure. For instances, it has been shown that measuring pressure overload by pulmonary artery catheter in patients hospitalised for acute decompensated heart failure is a useful tool for correct management of the disease [3].

However, measuring PCWP and LVFP is not essential in the challenging process of clinical management of heart failure for at least two main reasons. First, pulmonary interstitial fluid and alveolar oedema are not always the direct consequence of fluid accumulation but very often are the result of redistribution induced by vascular mechanisms [5]. Therefore, symptomatic pulmonary interstitial fluid can be present without fluid accumulation and high PCWP levels. Thus, measuring PCWP does not always allow early detection and correct management of exacerbations of heart failure. The Evaluation Study of Congestive Heart Failure and Pulmonary Artery Catheterization Effectiveness (ESCAPE) trial showed no impact on overall mortality and hospitalisation rates of pulmonary artery catheter-guided therapy over therapy guided by clinical evaluation and judgement alone in heart failure patients [4]. For this reason, clinicians should be aware of the clear difference existing between peripheral and pulmonary fluid, which are two different aspects of the phenomenon of pressure overload in congestive heart failure that can coexist and be symptomatic (clinical congestion) or be separate and even silent [5]. The second factor that limits the routine use of PCWP and LVFP in managing heart failure is that these data are not easy to acquire because they are measured by invasive and sophisticated meth-

ods, usually performed exclusively in the intensive care and cardiology settings.

## Evaluating congestion and pulmonary interstitial fluid

In daily practice, peripheral congestion and pulmonary interstitial fluid are assessed by clinical evaluation and some simple instrumental tests. However, clinical signs and symptoms of pressure overload are not always correlated with increased PCWP and LVFP. Often, symptoms of pressure overload, such as dyspnoea, pulmonary rales, weight gain with oedema and jugular venous distension may develop several days after the increase of the values of PCWP and LVFP [6–8]. These limitations can easily lead to undertreatment and underestimation of pulmonary interstitial fluid in patients with heart failure [6]. On the other hand, it is also known that clearance of symptoms during hospital stay of patients admitted for acute decompensated heart failure is not always linked to a stable real improvement of fluid accumulation. This could lead to incorrect titration of therapy and inappropriate early discharge. Finally, it has been shown that physical findings of fluid accumulation are neither sensitive nor specific for congestive heart failure, even if examination is performed by an expert physician [9, 10].

Guidelines of the European Society of Cardiology recognise chest radiography, cardiac natriuretic peptides and echocardiography (ECG) as essential tools for evaluating patients with known or suspected heart failure [11]. Conventional chest radiographic examination has several limitations when used to evaluate pulmonary interstitial fluid. It relies on signs limited by low specificity (cardiothoracic ratio) and high interobserver variability (redistribution of the bloodstream) [12]. Other radiological signs of pulmonary interstitial fluid, such as peribronchial cuffing and septal lines, are highly dependent on image quality and reader experience (clinician vs radiologist reading) [13, 14]. Radiological signs of vascular overload, such as vascular pedicle and azygos vein enlargement, have different values of accuracy depending on patient position during imaging (erect vs supine). Radiological evidence of pleural effusion reaches high specificity (but still low sensitivity) only when the most evident signs are considered (i.e. effusions exceeding the cranial margin of the diaphragm) [15]. Evaluation of radiological opacities shows high specificity but very low sensitivity. In general, each individual sign of heart failure at chest radiography is inadequate, with only moderate accura-

cy and particularly limited sensitivity, and the overall radiological impression reaches good accuracy in the emergency diagnosis of congestive heart failure only when a rigorous grading technique is applied [15]. Recognising congestive heart failure with the patient in the semierect or supine position using portable radiography depends to a greater extent on the presence of pulmonary oedema, a condition detected as central alveolar oedema only in more severe cases [16, 17]. Lastly, the absence of chest radiographic findings of pulmonary interstitial fluid does not exclude the presence of a high PCWP, even when  $>30$  mmHg [18].

Natriuretic hormones are useful in the follow-up of patients with heart failure, but some doubts remain about their utility in the initial diagnosis and the real cutoff values between normal and pathologic [19–23].

Ecocardiography still remains the standard criterion for diagnostic evaluation of patients with heart failure, especially for assessing systolic and diastolic cardiac function. Moreover, cardiac sonography can provide specific parameters, i.e. the ratio of peak early mitral flow velocity (E) divided by mitral annular early diastolic velocity (E0) by tissue Doppler imaging (E/E0), that strictly correlate with LVFP and allow indirect estimate of PCWP [24, 25]. However, this latter method, even though relatively easy to acquire at bedside, requires sophisticated and costly software. Moreover, it does not allow direct evaluation and follow-up of pulmonary interstitial fluid during acute decompensation.

Recognising, quantifying and monitoring pulmonary interstitial fluid is essential when evaluating patients with established or suspected heart failure. Assessing pulmonary interstitial fluid allows clinicians to recognise a cardiogenic cause of respiratory failure upon arrival in the emergency department or to evaluate appropriateness of discharge in hospitalised patients admitted for decompensated heart failure. Lung fluid accumulation can develop well before the appearance of clinical signs during the slow process of decompensation of established heart failure, and its early detection and treatment could prevent hospitalisation [7, 8]. Thus, in acutely dyspnoeic patients in the emergency department and in established heart failure outpatients and inpatients, pulmonary interstitial fluid should be routinely investigated to recognise heart failure, to treat impending worsening and to avoid inappropriately early discharge [5]. In all these settings, clinicians would benefit from a simple, repeatable bedside method for assessing and quantifying pulmonary interstitial fluid. This method should be sensitive enough to distinguish pulmonary interstitial fluid from peripheral congestion, which, as said, can be dissociated.

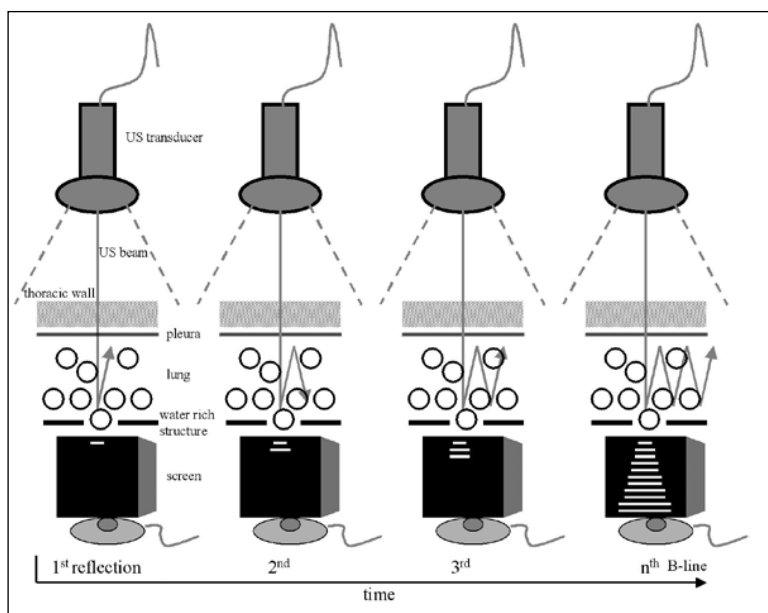
### Utility of lung ultrasound

In the past, respected sources considered sonography as

having inherent limitations in lung evaluation. Thoracic bones and pulmonary air content prevent progression of the ultrasound (US) beam and cause visualisation of artefacts [26]. This consideration, together with the widespread use of conventional chest radiographic examination and the development of new thoracic imaging technologies, prevented for many years progress in lung US procedures. Over the last two decades, the concept of using sonography as a real-time bedside clinical tool (point of care) in the hands of the same physician who is treating the patient is obtaining a growing consensus, which has led to a number of new applications. Among them, lung US is the most innovative. Quite recently, lung US opened new perspectives in the bedside evaluation of lung water, and many authors produced a growing number of papers showing its accuracy in diagnosing pulmonary diseases [27–29]. Rather than from technological progress, development of modern lung US procedures is mainly based on discovering the significance of sonographic artefacts [30]. Particularly, some vertical echogenic linear artefacts, designated as B-lines, are simple, noninvasive and semiquantitative signs of pulmonary interstitial fluid that can be evaluated at bedside. B-lines originate from the contrast of air and water, two elements having opposite acoustic impedance values [31]. In the lung, this is related to the contrast between air-filled and water-rich structures, which generate a phenomenon of reverberation visualised on the screen as linear vertical artefact B-lines (Fig. 1). In the normally aerated lung, only a very few B-lines can be detected by sonography (Fig. 2). When the water content increases and air decreases due to disease, the thickened interlobular septa and fluid into the alveolar spaces cause the appearance of multiple and diffuse B-lines (Fig. 3) [32].

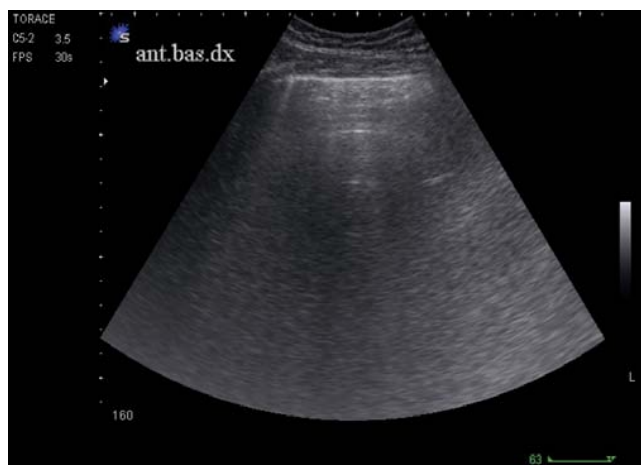### Interstitial syndrome

The relationship between diffuse lung interstitial involvement in diseases and the generation of multiple and bilateral sonographic B-lines was shown by a first study published in 1997 [32]. The authors examined a critically ill population ( $n=250$ ) undergoing invasive ventilation in the intensive care unit and compared lung US for B-lines with the radiological diagnoses (chest radiography and CT scan). B-lines showed high accuracy (sensitivity 93.4%, specificity 93.0%) in detecting interstitial syndrome, a condition of diffuse interstitial involvement with thickened interlobular septa and areas of ground-glass opacity. Only patients with cardiogenic pulmonary oedema, lesion pulmonary oedema (i.e. due to altered vascular permeability), interstitial pneumonia and pulmonary fibrosis showed diffuse and bilateral B-lines. Another study showed similar accuracy values of B-lines in the diagnosis of interstitial syndrome (sensitivity 85.7%, specificity 97.7%) [30]. The latter study enrolled 290 inpatients presenting to the emergency department and



**Fig. 1** Reverberation phenomenon generating B-lines. Passage of the ultrasound beam between elements with different acoustic impedance (air and water) generates these artefacts. This typically occurs in pulmonary oedema, where normally aerated alveoli coexist with water-rich structures (thickened interlobular septa and/or alveolar fluid content).

**Fig. 1** Spiegazione schematica del fenomeno di riverbero che genera le linee B. Il passaggio del fascio ultrasonoro tra elementi dotati di valori di impedenza acustica opposti (aria e fluidi) genera questi artefatti. Questo avviene tipicamente nell'edema polmonare, dove alveoli normalmente aerati coesistono con strutture ricche di fluidi (i setti interlobulari ispessiti e/o gli alveoli con contenuto fluido).



**Fig. 2** Ultrasound scan of a normal lung. In normally aerated lung and regular interstitium, the only image that can be visualised below the pleural line is the reflection of the chest wall from the probe to the parietal pleura, and no (or very few) vertical artefacts can be detected.

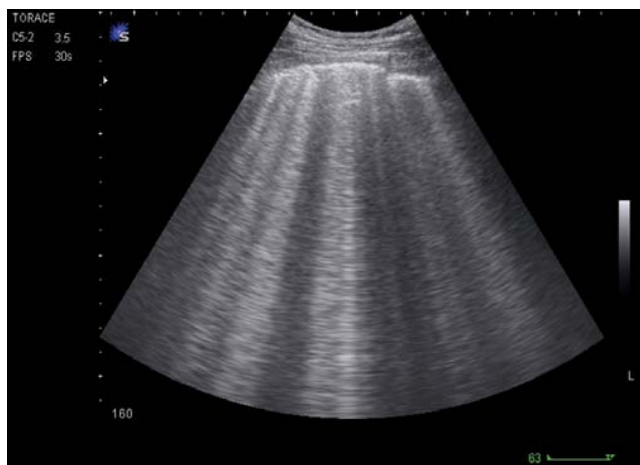**Fig. 2** Una scansione ecografica di un polmone normale. In caso di polmone normalmente aerato con interstizio regolare, l'unica immagine che può essere visualizzata è la riflessione sotto la linea pleurica della immagine della parete toracica dalla sonda alla pleura parietale, mentre non sono visualizzabili artefatti verticali (o eventualmente solo pochi di essi).

then admitted to beds in emergency medicine. The population examined was different from that of the previous study performed in the intensive care unit, because patients were spontaneously breathing, not critically ill, and were affected by more varied and multiple diseases. The sonographic pattern for B-lines was compared with chest radiography, CT scan and final clinical diagnosis. B-lines were detected mainly in patients with cardiogenic pulmonary oedema, interstitial pneumonia, multiple-foci bacterial pneumonia and

pulmonary fibrosis, with similar frequency and only slight difference in distribution between these diagnostic categories. The fundamental technique for diagnosing interstitial syndrome consisted of examining the anterior and lateral chest using four intercostal scans per side, corresponding to the upper and inferior areas anteriorly and the upper and basal areas laterally. A 3-5 MHz convex probe was used to search for B-lines. A positive scan was characterised by a minimum of three B-lines, whereas a positive examination was defined by at least two positive areas per side [33]. Simple detection of B-lines does not allow differentiation of the disease involving the lung interstitium, but other US signs can be used to confirm the diagnosis of congestive heart failure. Focused cardiac sonography can be performed using the same probe as that for lung examination, looking for global left ventricular function impairment, which will be detected in about 50% of cases of acute decompensated heart failure [34]. The same probe can also be used to detect an even smaller amount of anechoic pleural effusion, which is a frequent condition in heart failure, with a diagnostic accuracy higher than chest radiography and very close to CT scan [35, 36]. Finally, assessment of the proximal inferior vena cava can be also performed during the same US examination, and a pattern of dilation with limited or absent respiratory excursion of its diameter can confirm heart failure.

#### Measuring lung water

Since the publication of the first articles showing the usefulness of lung US in the diagnosis of interstitial syndrome in critically ill and emergency medicine patients, others have followed. Two studies performed in the cardiothoracic surgery setting showed the strict correlation of B-lines with the



**Fig. 3** Lung ultrasound scan showing multiple B-lines from a case of cardiogenic pulmonary oedema. When a similar pattern is visualised on multiple locations in the anterior and lateral chest, it is diagnostic of the interstitial syndrome.

*Fig. 3* Una scansione ecografica polmonare che mostra linee B multiple in un caso di edema polmonare cardiogeno. Quando un pattern simile viene visualizzato in multiple aree del torace anteriore e laterale, si fa diagnosi di sindrome interstiziale ecografica.

amount of extravascular lung water (EVLW). The number of B-lines detected by lung US in patients undergoing cardiac surgery was directly related to the amount of EVLW assessed by a semiquantitative chest radiography and the invasive thermodilution method [37, 38]. These papers paved the way for the use of lung US in the follow-up of pulmonary interstitial fluid in the cardiology setting in selected patients with known heart failure and without pulmonary diseases. The same authors also showed the importance of B-lines as a prognostic indicator, showing that mortality is related to the amount of lung water during acute decompensation [39]. Patients admitted to the cardiology department were followed for up to 40 months. The worst survival was observed in patients who exhibited a severe grade of sonographic B-lines at admission. Of note, conclusions from that paper can be applied only to a selected population studied in the cardiology setting [40]. The sonographic method used to measure extravascular lung water is based on semiquantification of B-lines, which is more time consuming than the eight-area technique explained earlier.

#### Monitoring pulmonary interstitial fluid

The strict correlation between B-lines and EVLW allows us to speculate about the usefulness of lung US in the follow-up of pulmonary interstitial fluid. An important application could be the evaluation of heart failure patients admitted to the hospital for acute decompensation. A recent study showed that B-lines significantly cleared after adequate treatment during the hospital stay in patients admitted for

acute decompensated heart failure [41]. Clearing of B-lines was significantly correlated with improved clinical symptoms and signs, the reduced signs of pulmonary interstitial fluid and oedema at chest radiography and lowered natriuretic peptides blood levels (Figs. 4 and 5). The time course of the process of B-lines clearing was variable depending on the severity of the clinical condition at presentation, with a mean of  $4.2 \pm 1.7$  days. The study authors concluded that B-lines could be easily used as a bedside method to assess the efficacy of treatment and clearing of pulmonary interstitial fluid in these hospitalised patients.

Another important contribution to demonstrating the usefulness of B-lines in the follow-up of pulmonary interstitial fluid comes from studies of lung US in evaluating patients undergoing haemodialysis [42, 43]. B-line resolution appears to occur in real time as fluid is removed from the body during the procedure. Once more, data from these studies support lung US as a useful method for evaluating real-time changes in EVLW and assessing pulmonary response to removal of fluid overload.

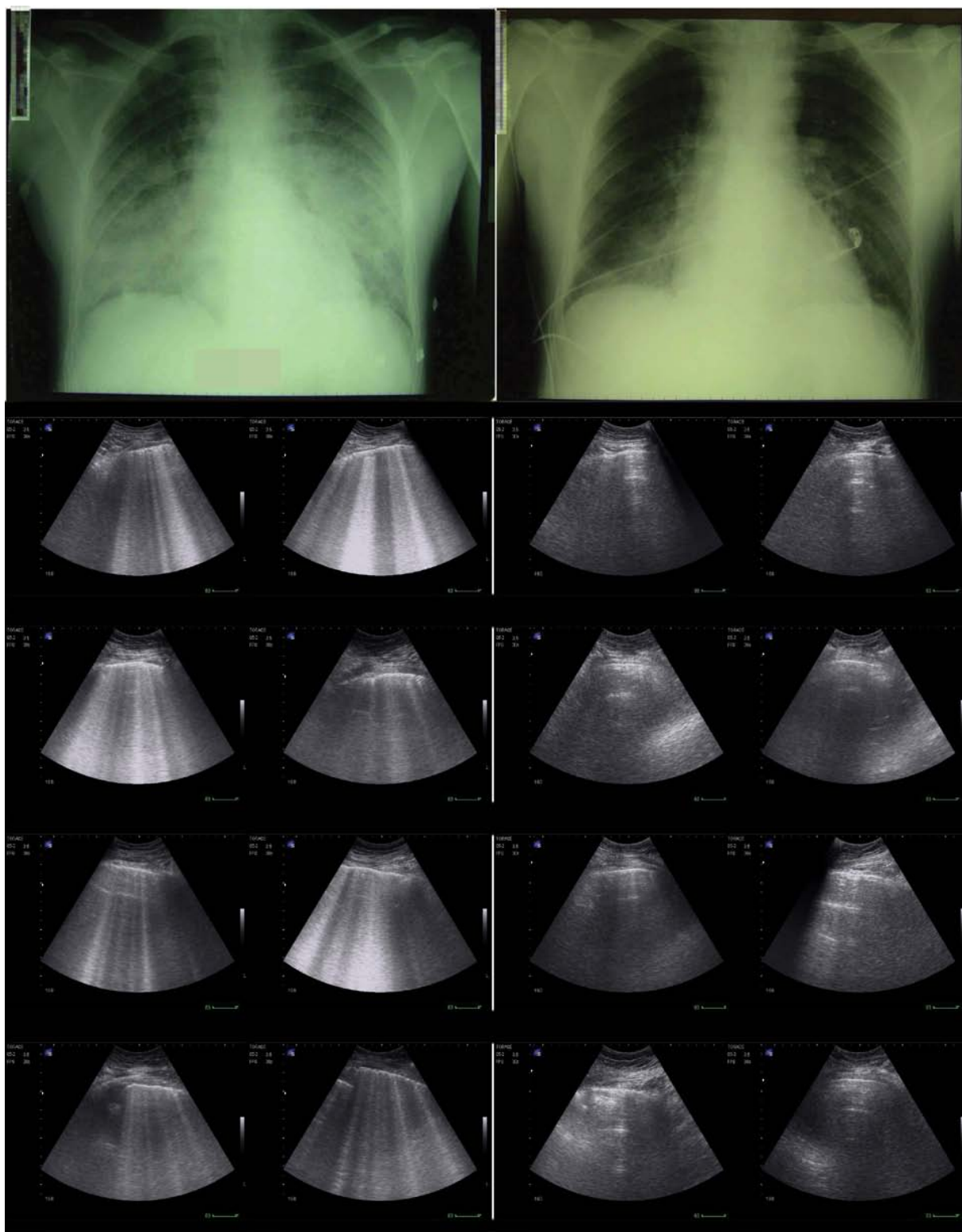
#### Differential diagnosis of cardiogenic pulmonary interstitial fluid

The primary diagnosis of pulmonary interstitial fluid in the emergency setting is crucial for the differential diagnosis between a cardiogenic and noncardiogenic respiratory failure. Some studies show the usefulness of B-lines as a primary diagnostic test in acute respiratory failure patients. Lung US appears to be particularly useful in differentiating between exacerbation of chronic obstructive pulmonary disease (COPD) and decompensated heart failure. In a study performed in dyspnoeic patients in the emergency department, diffuse B-lines were detected in 100% of patients with cardiogenic pulmonary oedema but was absent in 92% of cases with exacerbation of COPD and 98.75% of those with normal lungs [44]. The conclusion of the study was that sonographic detection of B-lines might help distinguish pulmonary oedema from exacerbation of COPD.

Other studies show the correlation between B-lines and natriuretic peptides in the primary evaluation of acute decompensated heart failure in the emergency department [45, 46]. Pulmonary interstitial fluid, sonographically demonstrated by B-lines, was strictly correlated with natriuretic hormones level. Conclusions from these studies is that lung US can be used alone or can provide additional predictive power to natriuretic peptides in the immediate evaluation of dyspnoeic patients and detection of the cardiac origin of the symptom.

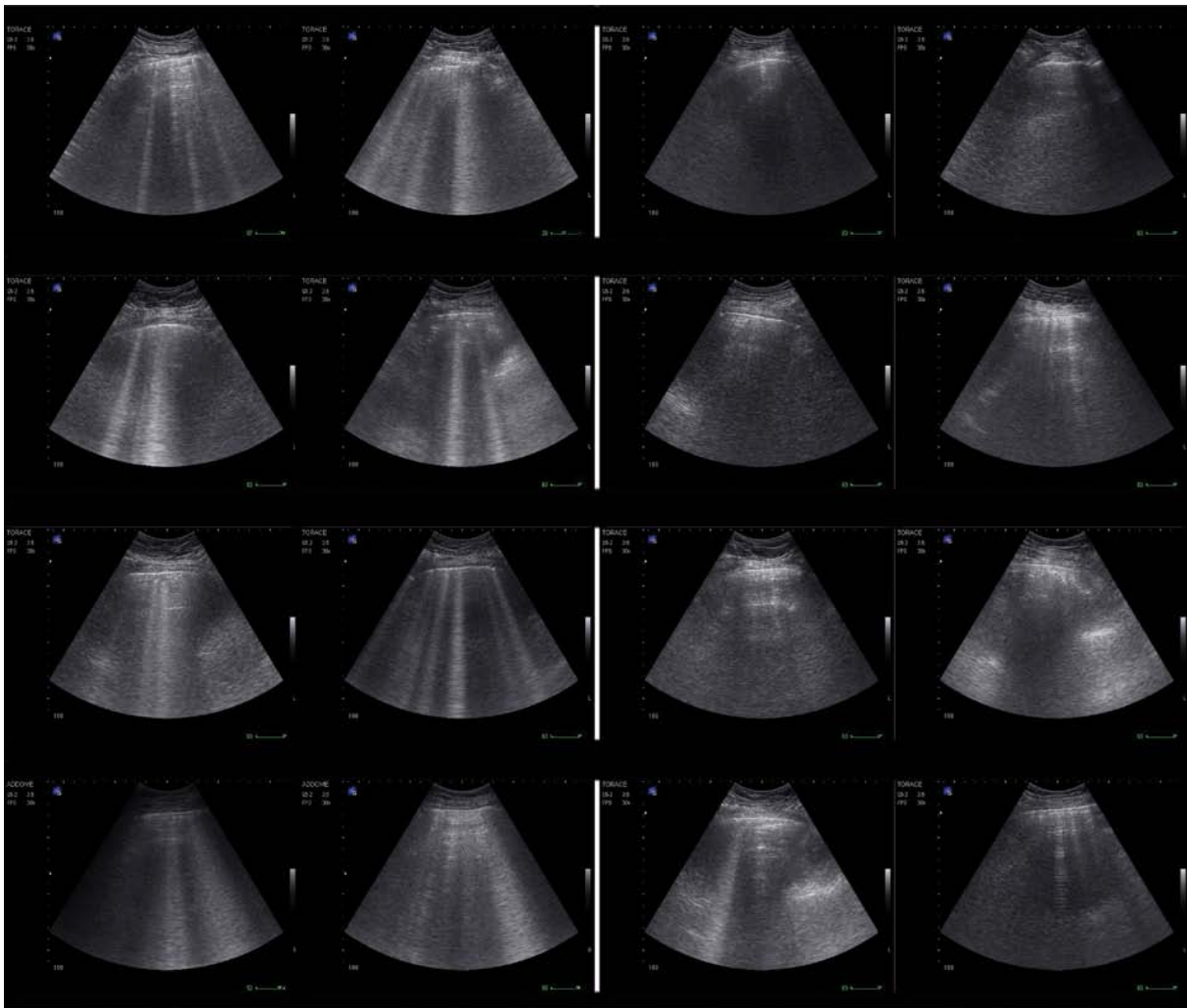
#### Scoring pulmonary interstitial fluid

The importance of lung US for B-lines is that it can also be



**Fig. 4** A case of severe acute cardiogenic pulmonary oedema. On the left panel, chest radiography and corresponding lung ultrasound pattern show multiple and diffuse B-lines in all eight anterolateral scans recorded at hospital admission. The right panel shows significant improvement after treatment at chest radiography and corresponding lung ultrasound. This was a case of severe cardiac failure refractory to treatment, where resolution of pulmonary oedema was obtained only 4 weeks after admission.

**Fig. 4** Un caso di grave edema polmonare acuto cardiogeno. A sinistra la radiografia del torace ed il corrispondente pattern ecografico registrati al momento del ricovero. L'ecografia mostra linee B multiple e diffuse in tutte le otto scansioni antero-laterali. A destra viene dimostrato il notevole miglioramento della radiografia del torace e dell'ecografia polmonare dopo terapia. Si trattava di un caso di grave insufficienza cardiaca inizialmente refrattaria alla terapia, nel quale la risoluzione dell'edema polmonare si è ottenuta solo dopo 4 settimane dal ricovero.



**Fig. 5** A case of acute cardiogenic pulmonary oedema. Right two columns: sonographic appearance of the eight anterolateral lungs scans showing multiple and diffuse B-lines. Left two columns: clearing of B-lines after treatment. In this less severe case than described in Fig. 4, clinical improvement was obtained after only 3 days of intensive medical and continuous positive airway pressure treatment.

*Fig. 5* Un altro caso di edema polmonare acuto cardiogeno. Le due colonne a destra mostrano le 8 scansioni antero-laterali con linee B multiple e diffuse. Le due colonne a sinistra mostrano la risoluzione delle linee B dopo trattamento. In questo caso meno grave del precedente in figura 4, il miglioramento clinico è stato ottenuto dopo soli 3 giorni di terapia medica intensiva e ventilazione in C-PAP.

considered a semiquantitative method for assessing EVLW. This is extremely important in the face of the possibility of monitoring heart-failure-related pulmonary interstitial fluid during the hospital stay and in the follow-up of outpatients. Scoring US B-lines is possible by counting the single artefacts on each thoracic scan [37, 38], by counting groups of B-lines and staging them in three different grades [39] or simply by counting the lung scans positive for B-lines [41]. Apart from the relative complexity of each method, B-lines can be objectively measured, thus allowing accurate quantification or semiquantification of EVLW, monitoring of pulmonary interstitial fluid and even indicating prognosis [37–43].

#### Limitations of lung ultrasound

The diagnostic accuracy of B-lines in heart failure is limited by lack of specificity. Although highly sensitive, B-lines are not specific signs of heart-failure-related pulmonary involvement. Rather, these artefacts are signs of interstitial fluid with thickened interlobular septa, which are not only linked to a cardiac disease but also to the pulmonary condition in cases of lesion oedema and inflammatory processes due to acute and chronic diseases, as happens in acute respiratory distress syndrome (ARDS), infections and fibrosis. Even if some authors have demonstrated significant differences in distribution and features of watery cardiogenic B-lines

from lesion B-lines, i.e. cardiogenic oedema versus ARDS oedema, this diversity can be hard to distinguish by using lung US only [47]. Basic B-line evaluation alone cannot be used to accurately distinguish various pulmonary conditions that share a similar sonographic pattern. Rather, B-lines identify a syndrome, namely, the sonographic interstitial syndrome, which can be caused by different pathogenic mechanisms, not only hydrostatic, but also due to inflammation and altered vascular permeability. However, despite this lack of specificity, the value of lung US for B-lines in the emergency setting or in selected cardiac patients has been well proven. The possibility of ruling out or ruling in some diseases by simply detecting or excluding a sonographic interstitial pattern, thus greatly reducing the diagnostic alternatives, has many useful consequences in the emergency setting. Moreover, the value of lung US can be dramatically improved when it is combined with other diagnostic tools, both clinical and instrumental.

Another limitation of lung US could be interreader variability in assessing sonographic images, especially when they refer to artefact analysis. However, learning to recognise B-lines is easy and based on a simple dichotomous response. Application of standardised diagnostic rules defining features of the B-line, a positive scan and a positive examination will help the process and make the technique highly reproducible. Studies analysing the inter operator variability of this technique show inter- and intraoperator variability to be

very low, with values around 4% [32, 33]. Of course, more studies are needed to further investigate this issue.

## Conclusions

In heart failure patients, congestion is an extremely complex condition. Shifting of the fluids in the lungs causes pulmonary interstitial fluid and alveolar oedema, which is the main cause of hospitalisation. Accurate diagnosis and follow-up of pulmonary interstitial fluid in heart failure is important in many scenarios: (1) in the emergency setting, for the differential diagnosis of acute dyspnoea; (2) in inpatient management, to titrate therapy and decide timing of discharge; (3) in outpatients, to prevent the impending decompensation and avoid hospitalisation. Commonly used diagnostic tools, both clinical and instrumental, have several limitations that can be improved by considering new methods. Lung US is an easy-to-use, low-cost technology that allows accurate noninvasive bedside assessment of pulmonary interstitial fluid. Its usefulness is related to the easy detection of certain specific vertical artefacts called B-lines. The great diagnostic potential of lung US, together with careful consideration of the limits of the methodology and awareness of the need to integrate the sonographic data with other diagnostic tools, will probably make B-lines a state-of-the-art biomarker of pulmonary interstitial fluid.

**Conflict of interest** None

## References/Bibliografia

- Gheorghiade M, Zannad F, Sopko G et al (2005) International Working Group on Acute Heart Failure Syndromes. Acute heart failure syndromes: current state and framework for future research. *Circulation* 112:3958–3968
- Gheorghiade M, Filippatos G, De Luca L, Burnett J (2006) Congestion in acute heart failure syndromes: an essential target of evaluation and treatment. *Am J Med* 119(Suppl 1):S3–S10
- Shah MR, Hasselblad V, Stevenson LW et al (2005) Impact of the pulmonary artery catheter in critically ill patients: meta-analysis of randomized clinical trials. *JAMA* 294:1664–1670
- Binanay C, Califf RM, Hasselblad V et al (2005) ESCAPE Investigators and ESCAPE Study Coordinators. Evaluation study of congestive heart failure and pulmonary artery catheterization effectiveness: the ESCAPE trial. *JAMA* 294:1625–1633
- Picano E, Gargani L, Gheorghiade M (2010) Why, when, and how to assess pulmonary congestion in heart failure: pathophysiological, clinical, and methodological implications. *Heart Fail Rev* 15:63–72
- Chakko S, Woska D, Martinez H et al Clinical, radiographic, and hemodynamic correlations in chronic congestive heart failure: conflicting results may lead to inappropriate care. *Am J Med* 90:353–359
- Adamson PB, Magalski A, Braunschweig F et al (2003) Ongoing right ventricular hemodynamics in heart failure: clinical value of measurements derived from an implantable monitoring system. *J Am Coll Cardiol* 41:565–571
- Yu CM, Wang L, Chau E et al (2005) Intrathoracic impedance monitoring in patients with heart failure: correlation with fluid status and feasibility of early warning preceding hospitalization. *Circulation* 112:841–848
- Remes J, Miettinen H, Reunanen A, Pyörälä K (1991) Validity of clinical diagnosis of heart failure in primary health care. *Eur Heart J* 12:315–321
- Badgett RG, Lucey CR, Mulrow CD (1997) Can the clinical examination diagnose left-sided heart failure in adults? *JAMA* 277:1712–1719



11. Swedberg K, Cleland J, Dargie H et al (2005) Task Force for the Diagnosis and Treatment of Chronic Heart Failure of the European Society of Cardiology. Guidelines for the diagnosis and treatment of chronic heart failure: executive summary (update 2005): The Task Force for the Diagnosis and Treatment of Chronic Heart Failure of the European Society of Cardiology. *Eur Heart J* 26:1115–1140
12. Collins SP, Lindsell CJ, Storrow AB, Abraham WT (2006) ADHERE Scientific Advisory Committee, Investigators and Study Group. Prevalence of negative chest radiography results in the emergency department patient with decompensated heart failure. *Ann Emerg Med* 47:13–18
13. Nieminen MS, Böhm M, Cowie MR et al (2005) ESC Committee for Practice Guideline (CPG). Executive summary of the guidelines on the diagnosis and treatment of acute heart failure: the Task Force on Acute Heart Failure of the European Society of Cardiology. *Eur Heart J* 26:384–416
14. Lange NR, Schuster DP (1999) The measurement of lung water. *Crit Care* 3:R19–R24
15. Studler U, Kretschmar M, Christ M et al (2008) Accuracy of chest radiographs in the emergency diagnosis of heart failure. *Eur Radiol* 18:1644–1652
16. White CS, Davis SD, Aquino SL et al (2006) Expert Panel on Thoracic Imaging. Congestive heart failure. [online publication]. Reston (VA): American College of Radiology (ACR) [www.guideline.gov/content.aspx?id=9604](http://www.guideline.gov/content.aspx?id=9604)
17. Gluecker T, Capasso P, Schneyder P et al (1999) Clinical and radiologic features of pulmonary edema. *Radiographics* 19:1507–1531
18. Mahdyoon H, Klein R, Eyler W et al (1989) Radiographic pulmonary congestion in endstage congestive heart failure. *Am J Cardiol* 63:625–627
19. Troughton RW, Frampton CM, Yandle TG et al (2000) Treatment of heart failure guided by plasma aminoterminal brain natriuretic peptide (N-BNP) concentrations. *Lancet* 355:1126–1130
20. Silver MA, Maisel A, Yancy CW et al (2004) BNP Census Panel 2004: a clinical approach for the diagnostic, prognostic, screening, treatment monitoring, and therapeutic roles of natriuretic peptides in cardiovascular diseases. *Congest Heart Fail* 10(Suppl 3):1–30
21. Di Somma S, Magrini L, Mazzone M et al (2007) Decrease in NTproBNP plasma levels indicates clinical improvement of acute decompensated heart failure. *Am J Emerg Med* 25:335–339
22. Valle R, Aspromonte N, Giovinazzo P et al (2008) B-type natriuretic Peptide-guided treatment for predicting outcome in patients hospitalized in sub-intensive care unit with acute heart failure. *J Card Fail* 14:219–224
23. Maisel A, Mueller C, Adams K Jr et al (2008) State of the art: using natriuretic peptide levels in clinical practice. *Eur J Heart Fail* 10:824–839
24. Nagueh SF, Middleton KJ, Kopelen HA et al (1997) Doppler tissue imaging: a noninvasive technique for evaluation of left ventricular relaxation and estimation of filling pressures. *J Am Coll Cardiol* 30:1527–1533
25. Nagueh SF, Appleton CP, Gillebert TC et al (2009) Recommendations for the evaluation of left ventricular diastolic function by echocardiography. *Eur J Echocardiogr* 10:165–193
26. Herth FJF, Becker HD (2003) Transthoracic ultrasound. *Respiration* 70:87–94
27. Lichtenstein DA (2007) Ultrasound in the management of thoracic disease. *Crit Care Med* 35(Suppl):S250–S261
28. Picano E, Frassi F, Agricola E et al (2006) Ultrasound lung comets: a clinically useful sign of extravascular lung water. *J Am Soc Echocardiogr* 19:356–363
29. Volpicelli G, Cardinale L, Garofalo G, Veltri A (2008) Usefulness of lung ultrasound in the bedside distinction between pulmonary edema and exacerbation of COPD. *Emerg Radiol* 15:145–151
30. Lichtenstein DA, Mezière G, Lascols N et al (2005) Ultrasound diagnosis of occult pneumothorax. *Crit Care Med* 33:1231–1238
31. Soldati G, Copetti R, Sher S (2009) Sonographic interstitial syndrome: the sound of lung water. *J Ultrasound Med* 28:163–174
32. Lichtenstein D, Mezière G, Biderman P et al (1997) The comet tail artifact. An ultrasound sign of alveolar-interstitial syndrome. *Am J Respir Crit Care Med* 156:1640–1646
33. Volpicelli G, Mussa A, Garofalo G et al (2006) Bedside lung ultrasound in the assessment of alveolar-interstitial syndrome. *Am J Emerg Med* 24:689–696
34. Vasan RS, Larson MG, Benjamin EJ et al (1999) Congestive heart failure in subjects with normal versus reduced left ventricular ejection fraction: prevalence and mortality in a population-based cohort. *J Am Coll Cardiol* 33:1948–1955
35. Kocijancic I, Vidmar K, Ivanovi-Herceg Z (2003) Chest sonography versus lateral decubitus radiography in the diagnosis of small pleural effusions. *J Clin Ultrasound* 31:69–74
36. Lichtenstein D, Goldstein I, Mourgeon E et al (2004) Comparative diagnostic performances of auscultation, chest radiography, and lung ultrasonography in acute respiratory distress syndrome. *Anesthesiology* 100:9–15
37. Jambrik Z, Monti S, Coppola V et al (2004) Usefulness of ultrasound lung comets as a nonradiologic sign of extravascular lung water. *Am J Cardiol* 93:1265–1270
38. Agricola E, Bove T, Oppizzi M et al “‘Ultrasound comet-tail images’”: a marker of pulmonary edema: a comparative study with wedge pressure and extravascular lung water. *Chest* 127:1690–1695
39. Frassi F, Gargani L, Tesorio P et al (2007) Prognostic value of extravascular lung water assessed with ultrasound lung comets by chest sonography in patients with dyspnea and/or chest pain. *J Cardiac Fail* 13:830–835
40. Volpicelli G (2008) Are ultrasound lung comets useful as prognostic indicator in any patients with dyspnea or chest pain? *J Card Fail* 14:263–264
41. Volpicelli G, Caramello V, Cardinale L et al (2008) Bedside ultrasound of the lung for the monitoring of acute decompensated heart failure. *Am J Emerg Med* 26:585–591
42. Noble VE, Murray AF, Capp R et al (2009) Ultrasound assessment for extravascular lung water in patients undergoing hemodialysis. Time course for resolution. *Chest* 135:1433–1439
43. Mallamaci F, Benedetto FA, Tripepi R et al (2010) Detection of pulmonary congestion by chest ultrasound in dialysis patients. *JACC Cardiovasc Imaging* 3:586–594
44. Lichtenstein D, Mezière G (1998) A lung ultrasound sign allowing bedside distinction between pulmonary edema and COPD: the comet-tail artifact. *Intensive Care Med* 24:1331–1334

- 
45. Gargani L, Frassi F, Soldati G et al (2008) Ultrasound lung comets for the differential diagnosis of acute cardiogenic dyspnoea: a comparison with natriuretic peptides. *Eur J Heart Fail* 10:70–77
46. Liteplo AS, Marill KA, Villen T et al (2009) Emergency thoracic ultrasound in the differentiation of the etiology of shortness of breath (ETUDES): sonographic B-lines and N-terminal pro-brain-type natriuretic peptide in diagnosing congestive heart failure. *Acad Emerg Med* 16:201–210
47. Copetti R, Soldati G, Copetti P (2008) Chest sonography: a useful tool to differentiate acute cardiogenic pulmonary edema from acute respiratory distress syndrome. *Cardiovasc Ultrasound* 29:6–16